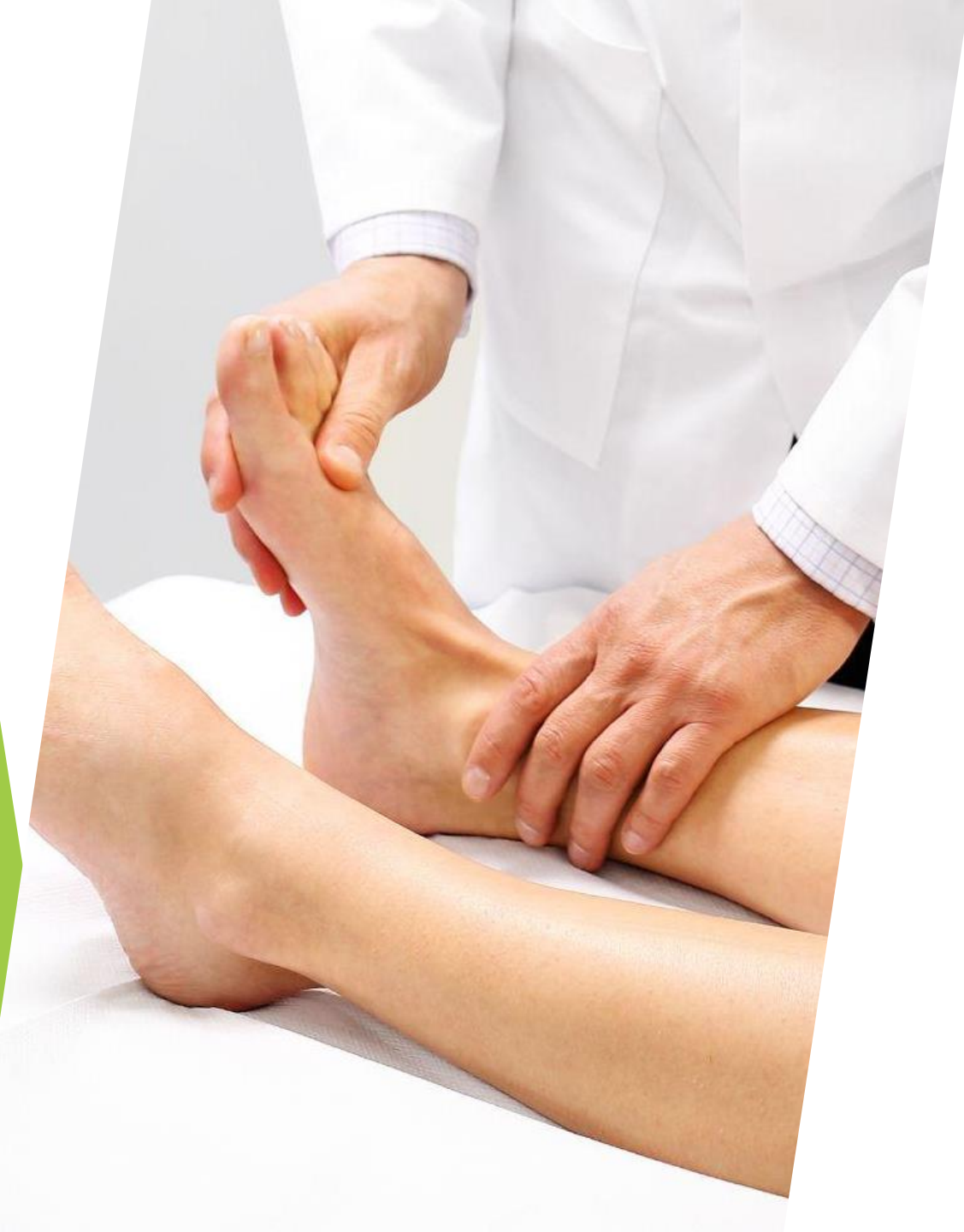

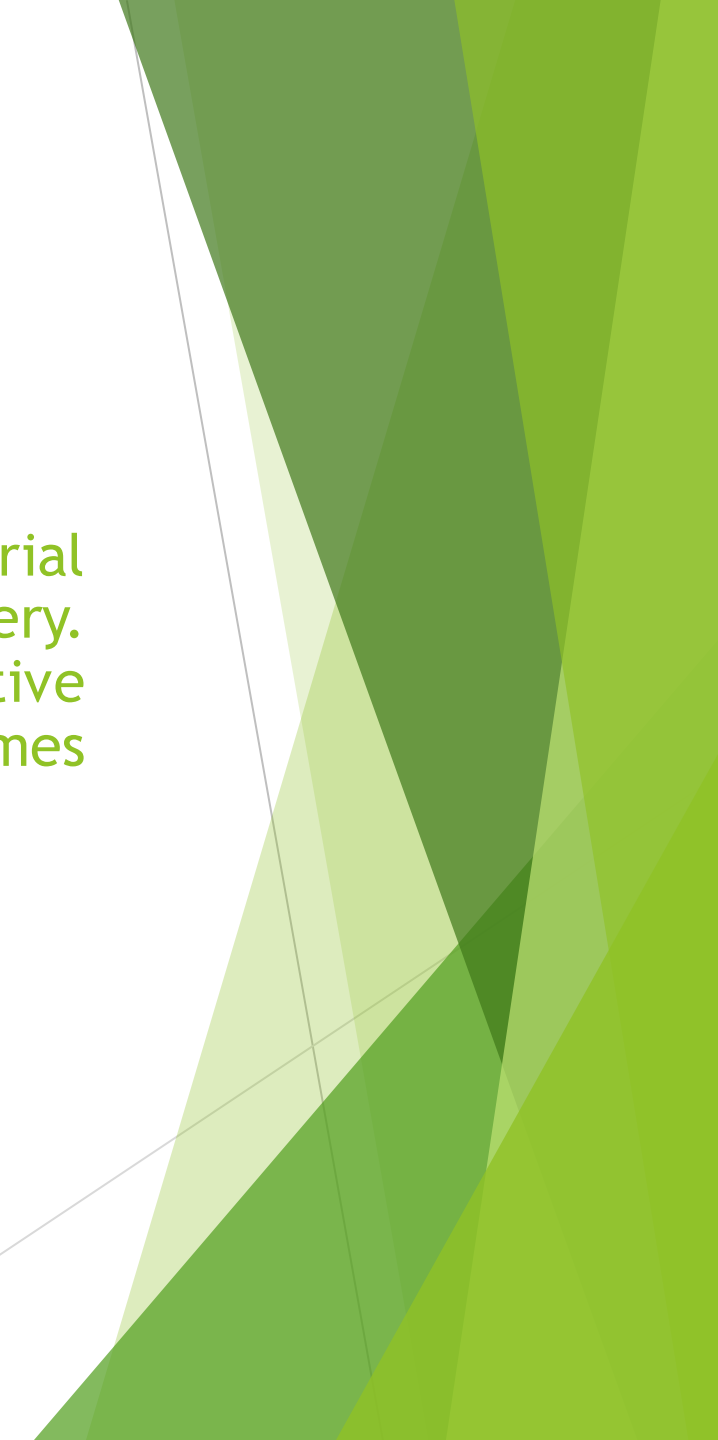The background of the slide features a blurred ECG (heart rate) line on a grid, transitioning from a light blue/purple hue on the left to a white center, and then to various shades of green on the right. The ECG line is a dark blue/black color.

Vascular Assessment pre-Nail Surgery

- ▶ Patrick McGill BSc. PGCert NMP.
MSc. AFHEA
- ▶ Podiatrist / Lecturer Podiatric
Medicine, Ulster University
- ▶ Emily Haworth BSc (hons) PGCert
PSM. PGDip Rcsi MSc.
- ▶ Advanced Specialist Podiatrist



Importance of Arterial
Assessment Pre-Nail Surgery.
Ensuring Safe and Effective
Outcomes



Why Arterial Assessment is Crucial

Importance of vascular health in lower limb surgeries



Are we happy there is adequate arterial flow to allow for healing?



Risks associated with poor arterial supply, tissue loss, amputation, death.

The 3Ps of peripheral arterial disease assessment



1. **Pulses** (palpation at foot)
2. **Phases** (doppler waveforms)
3. **Pressures** (mmHg ankles, toes)

No one of the 3Ps is reliable enough in isolation to exclude or confirm peripheral arterial disease

As podiatrists & nurses, if we use these simple clinical assessment tools routinely...

WE WILL play a safer role in wound healing and amputation prevention

(NICE CG147 2012, GVG 2019, NWCS 2022 & IWGDF 2023 Guidelines)

A microscopic view of red blood cells, showing their characteristic biconcave disc shape and reddish color. The cells are scattered across the frame, with some in sharp focus and others blurred in the background. The overall color palette is warm, dominated by reds and oranges.

Basics of Arterial Flow

- ▶ Role of arteries in blood supply
- ▶ Common arterial issues (e.g., atherosclerosis, peripheral artery disease, CLTI)
- ▶ Impact on healing and surgical outcomes

What tools do we have as clinicians?

Hands & Eyes

Pulse Palpation

- ▶ Importance of checking pulses
- ▶ Common sites for pulse palpation (e.g., dorsalis pedis, posterior tibial, Popliteal)
- ▶ How to palpate pulses effectively



Understanding Pulse Phases

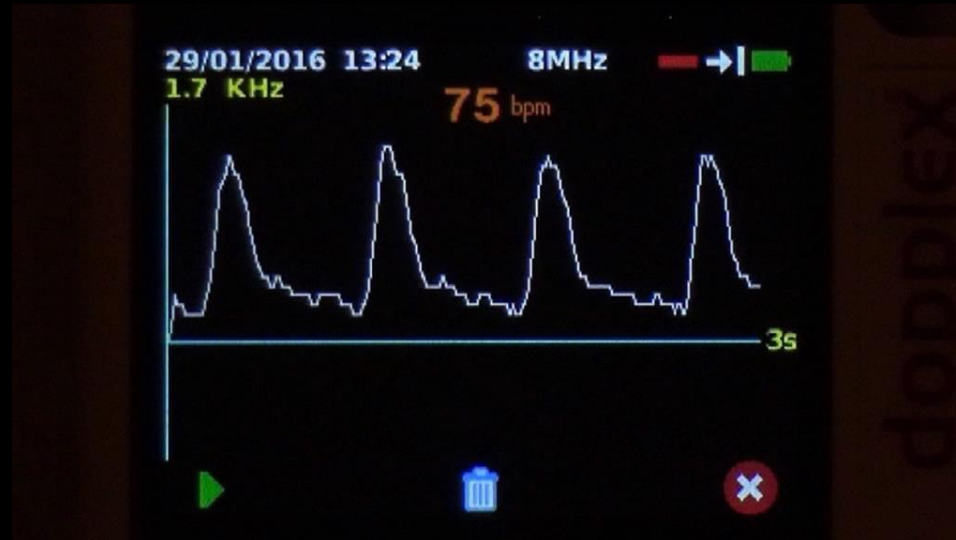- ▶ Explanation of pulse phases (e.g., systolic, diastolic)
- ▶ Significance of pulse phases in arterial assessment
- ▶ Identifying abnormalities in pulse phases



Doppler phases

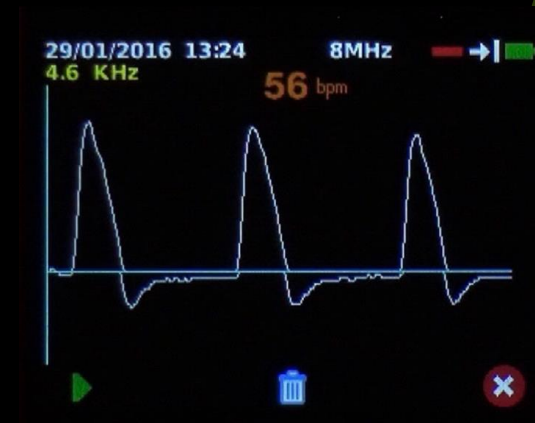Multi-phasic (Tri / Bi)?

Mono-phasic?



Doppler phases

Multi-phasic (Tri / Bi)?
Mono-phasic?



Next time you listen... think do you hear:

- Waa-oo
- Ba-con



Using ABPI for Assessment

- ▶ What is ABPI?
- ▶ How to measure ABPI
- ▶ Interpretation of ABPI results
- ▶ Clinical significance of ABPI in lower limb assessment

Using TBPI for Detailed Assessment

What is TBPI?



How to measure TBPI

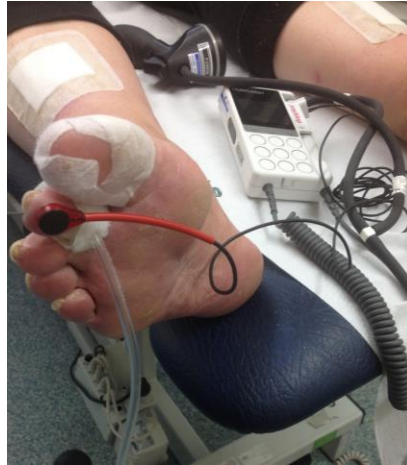
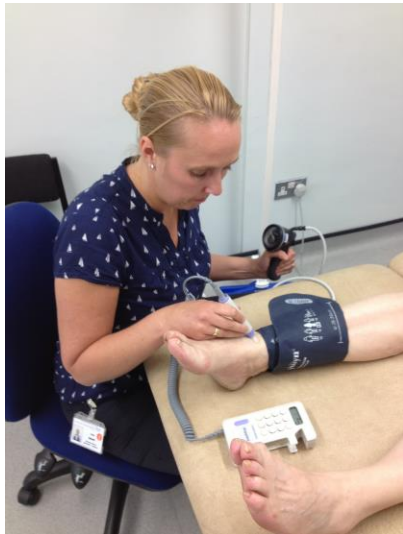
Interpretation of TBPI results



When to use TBPI over ABPI

Ankle & toe pressures - Why don't we?



Summary of findings

Survey Participants	Total	Pulse palpation	Doppler phases	ABPI	TBPI	
Aus / NZ	447	97%	74%	34%	19%	Tehan et al, 2015
UK	588	51%	72%	32%	6%	Tehan et al, 2019

Barriers to performing vascular assessment

	Aus /NZ	UK
Lack of time	66%	52%
Lack of equipment	28%	42%
Lack of experience		34%

ABPI < 10 minutes
Ankle systolic pressure < 5 minutes
Toe systolic pressure < 3 minutes

Woundcare at 12 weeks > 720 minutes

Consequence: teams and patient risk

Absent from team culture
& assessment processes


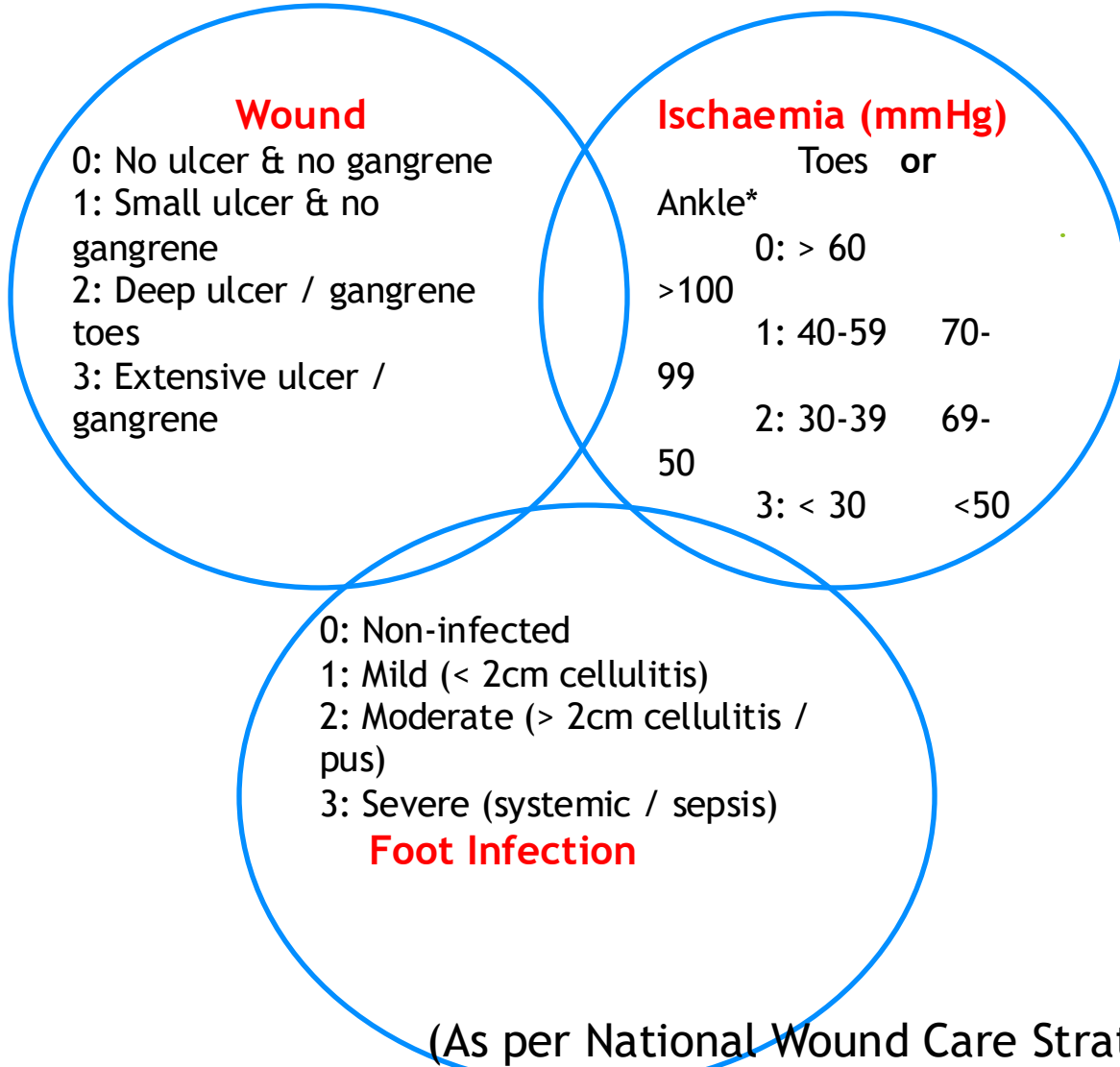
=

Done late or not at all...



Wifi Wound Classification for CLTI

(Mills et al 2014)



Wifi helps determine the current risk of amputation with any lower limb wound:

1. *Very low risk of amputation*
2. *Low risk of amputation*
3. *Moderate risk of amputation*
4. *High risk of amputation*

This helps identify the need for any referral to a Vascular Team and the urgency of that referral

(As per National Wound Care Strategy Guidelines 2021 & the WGD 2023 Guidelines)

Doppler Ultrasound in Arterial Assessment



Basics of Doppler ultrasound



How Doppler ultrasound works

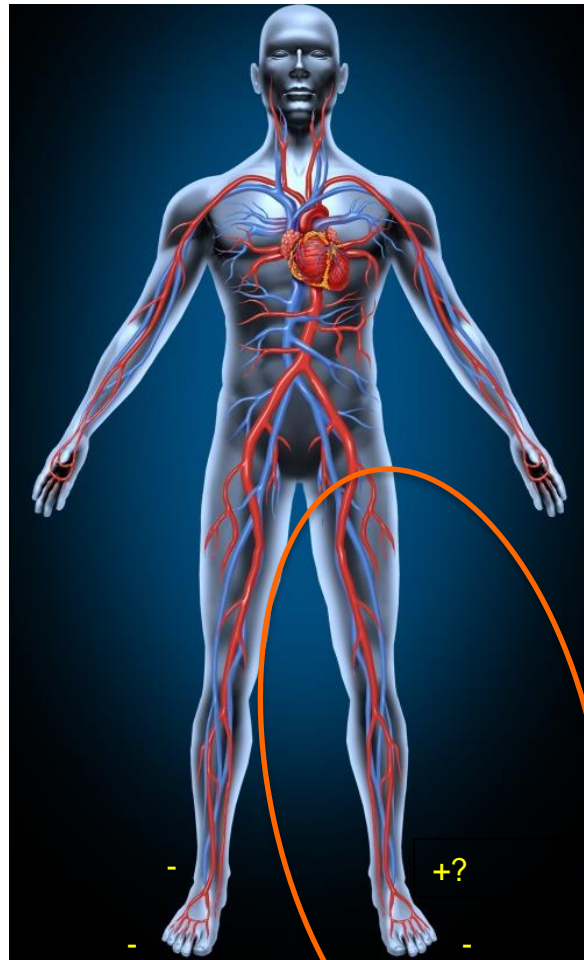
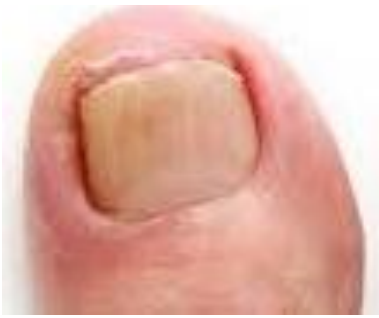

Benefits of using Doppler for arterial assessment



Identifying arterial flow issues with Doppler

Case example: Annie



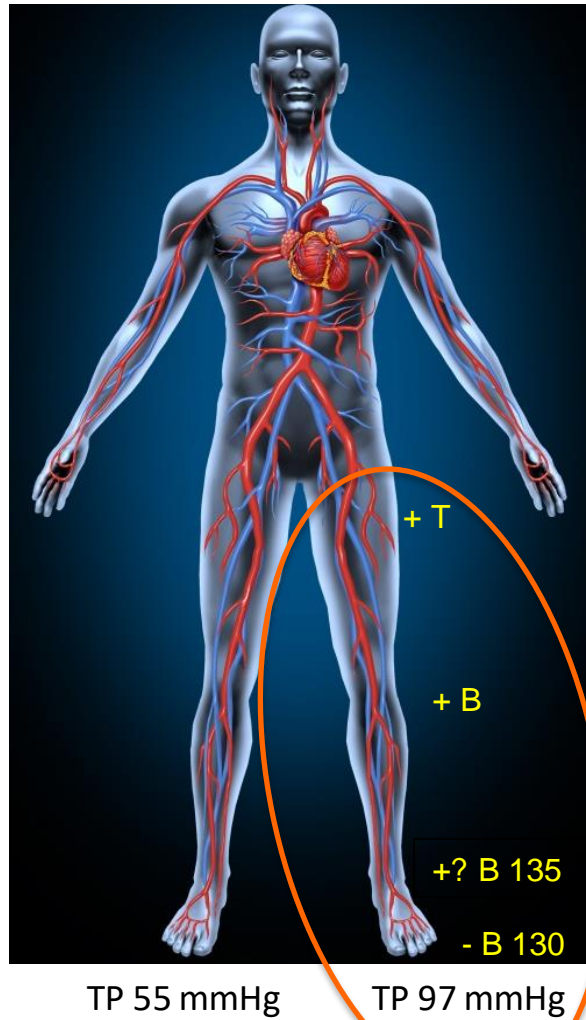
- Age 68, hypertension
- Diabetes, HbA1c 58
- Known PAD – right leg
- Quit smoking last year
- OA knee, limits activity
- Feet fairly warm
- Pulses palpable left foot?
- **Chronic involuted left 1st nail with recurrent local infections – needs nail surgery?**

Can we do it safely and proactively?





Case example: Annie - single limb of concern arterial assessment ... in 5 - 10 mins



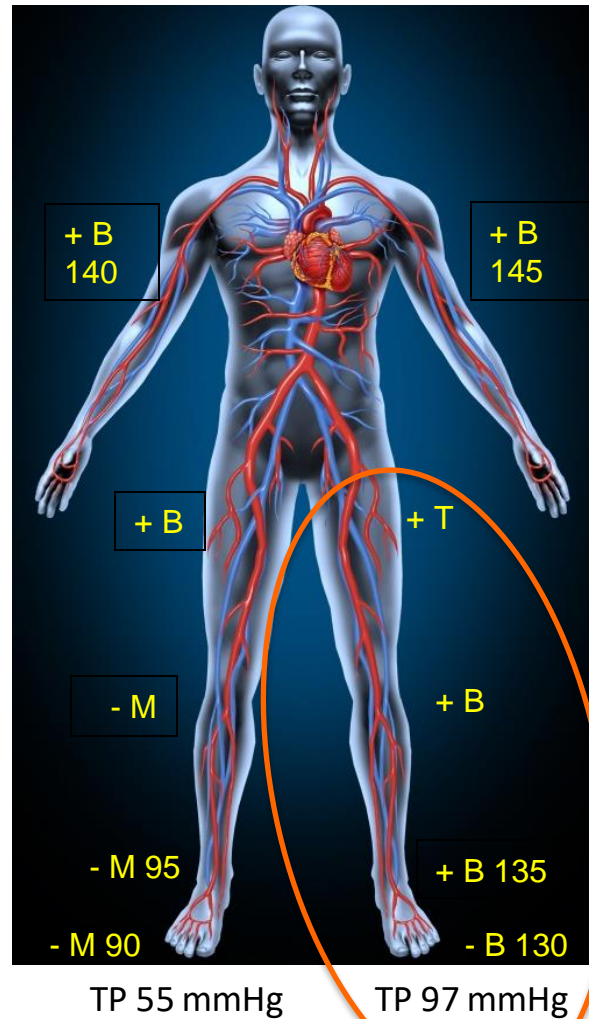
- Age 68, hypertension
- Diabetes, HbA1c 58
- Known PAD – right leg
- Quit smoking last year
- OA knee, limits activity
- Feet fairly warm
- Pulses palpable left foot?
- **Chronic involuted left 1st nail with recurrent local infections – needs nail surgery?**

Can we do it safely and proactively?

- Triaged from PN to High Risk Foot Team
- 3Ps single limb of concern assessment
- Phone call with Vascular Team to discuss
- Nail surgery provided – healed well



Case example: Annie - or a full peripheral arterial assessment ... in 20 mins



- Age 68, hypertension
- Diabetes, HbA1c 58
- Known PAD – right leg
- Quit smoking last year
- OA knee, limits activity
- Feet fairly warm
- Pulses palpable left foot?
- **Chronic involuted left 1st nail with recurrent local infections – needs nail surgery?**

Can we do it safely and proactively?

Left limb
ABPI: 0.9
TBPI: 0.7

- Triaged from PN to High Risk Foot Team
- 3Ps single limb of concern assessment
- Phone call with Vascular Team to discuss
- Nail surgery provided – healed well



Conclusion and Questions

- ▶ Summary of key points
- ▶ Importance of thorough arterial assessment
- ▶ Open floor for questions and discussion