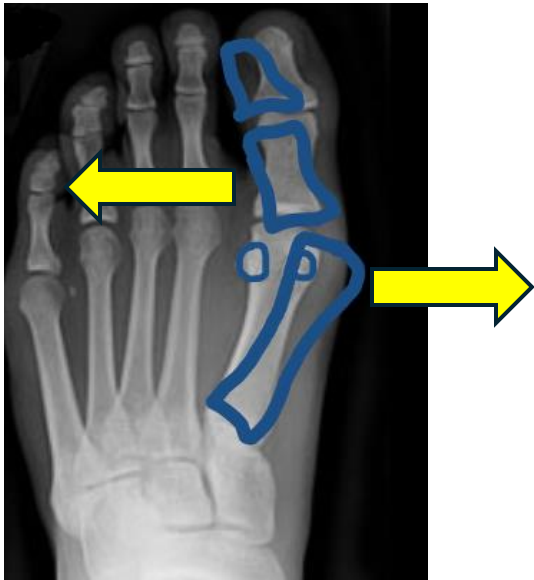
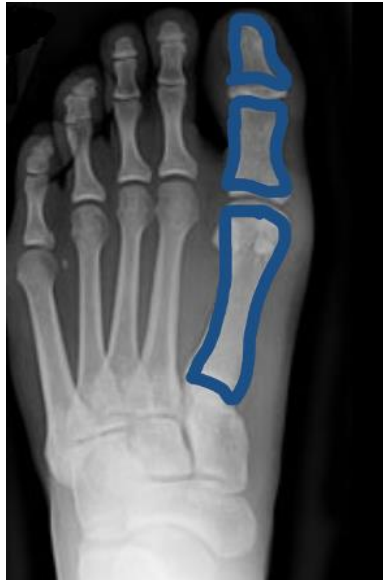
What is Hallux Valgus? (HV)



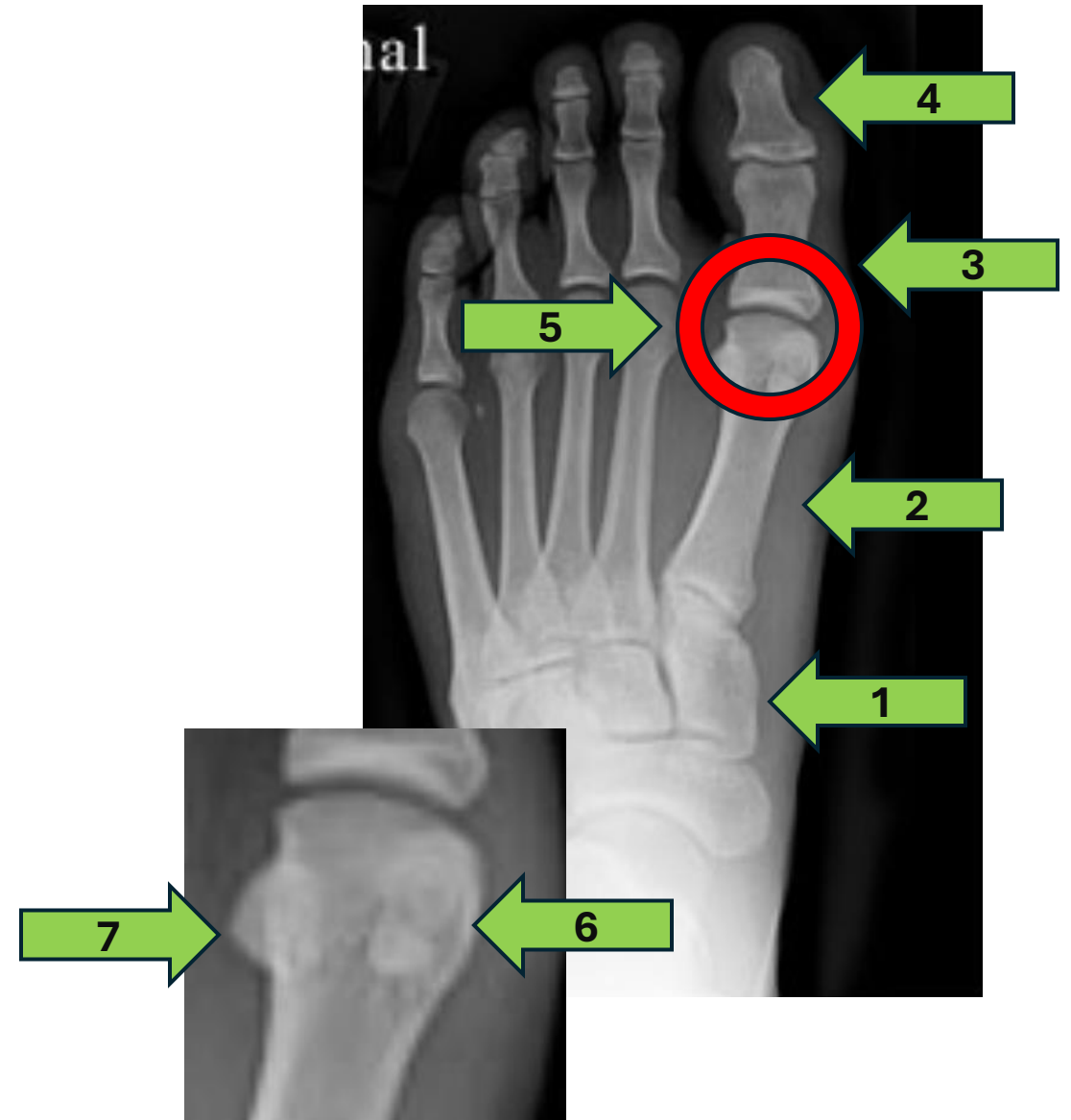
Signs and Symptoms of HIV

Clinical Signs of HIV

Clinical Symptoms of HIV

Bones

- 1.
- 2.
- 3.
- 4.
- 5.
- 6.
- 7.



Ligaments surrounding the 1st MTPJ

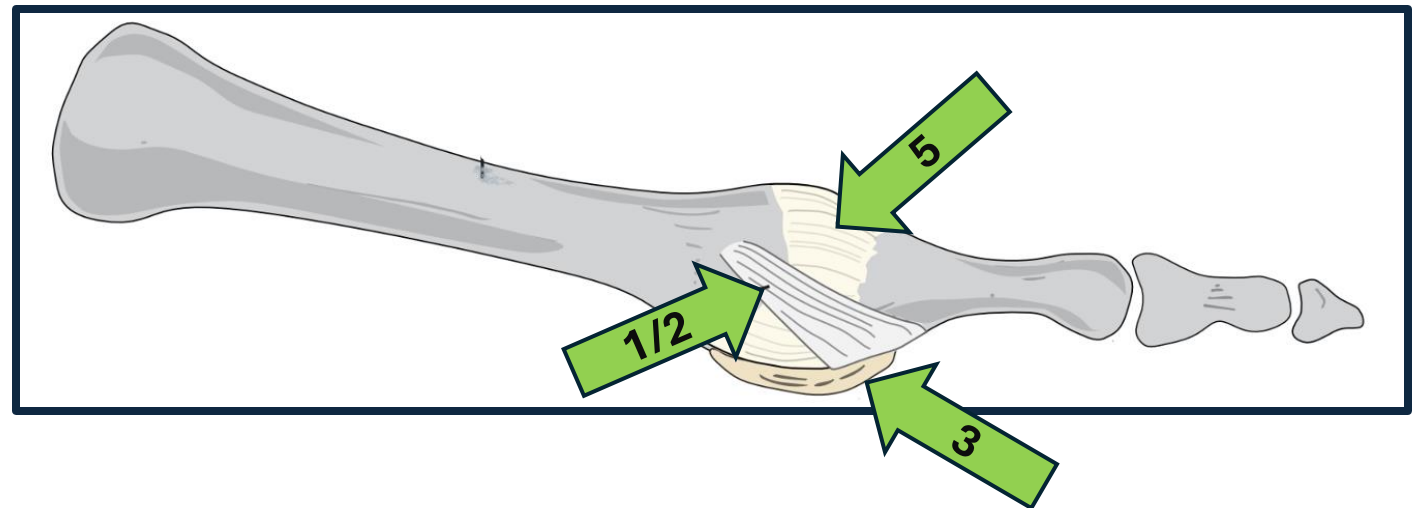
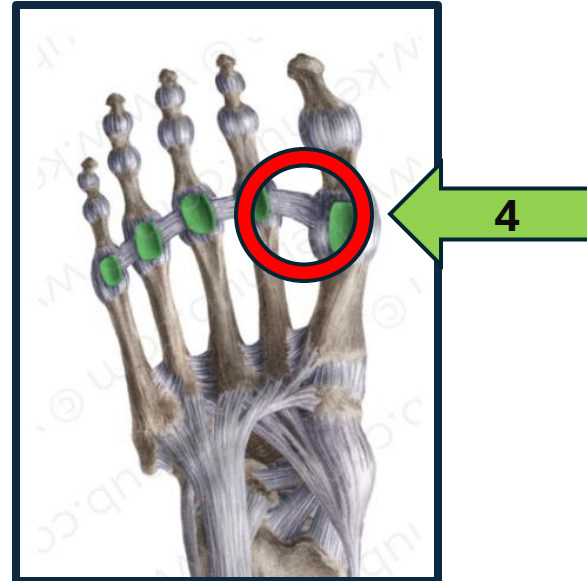
1.

2.

3.

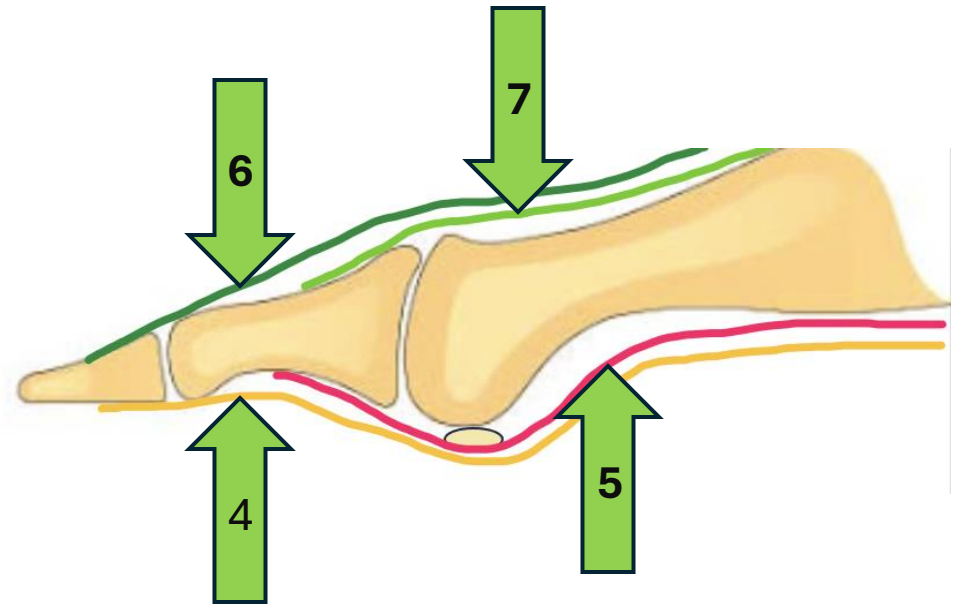
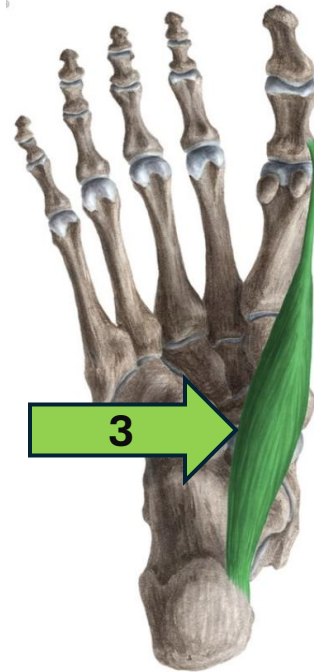
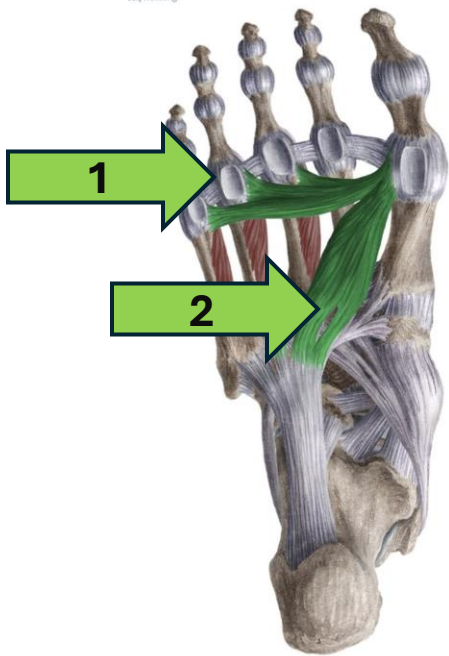
4.

5.



Muscles

- 1.
- 2.
- 3.
- 4.
- 5.
- 6.
- 7.

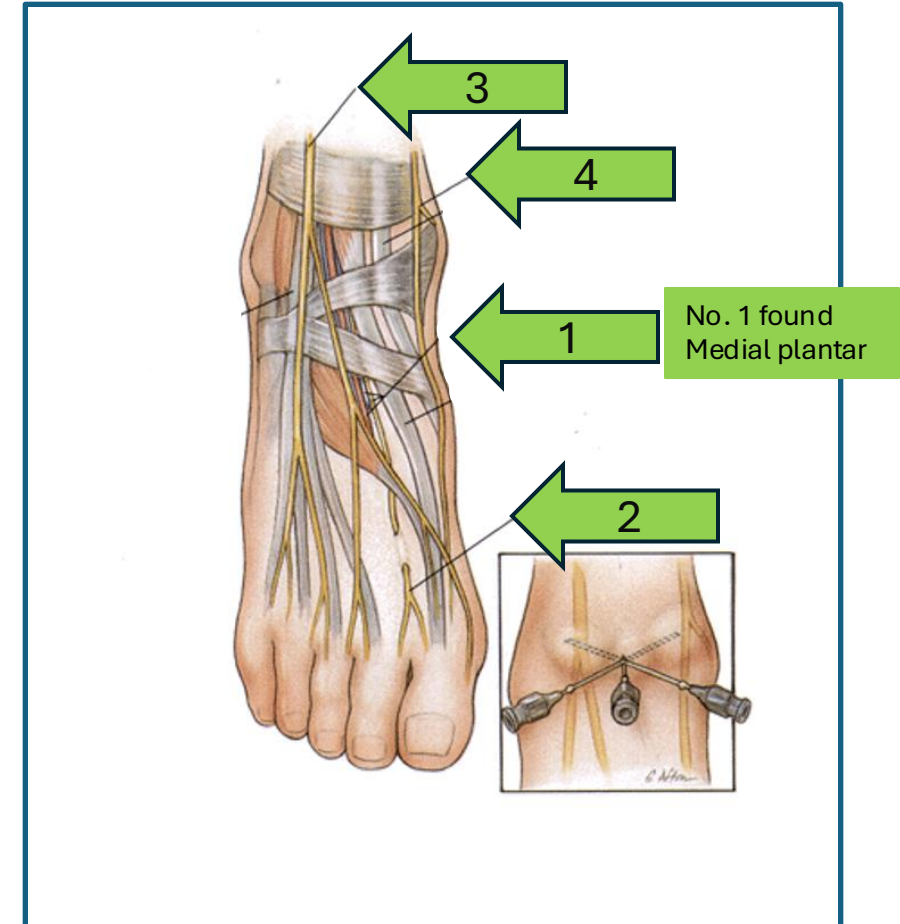


Nerves

The **1st MTP joint** is supplied by both sensory and motor branches of the nerves of the foot

Nerve


- | Nerve | Region Supplied |
|-------|--|
| 1. | Plantar aspect of the joint |
| 2. | Dorsal aspect (1st web space) |
| 3. | Dorsal aspect (lateral/overlying skin) |
| 4. | Medial side (variable contribution) |



Intrinsic & Extrinsic

Intrinsic predisposing factors to consider

Extrinsic predisposing factors to consider



Case Study

- **Mrs. Jane Walker, Age: 52**
- **Occupation:** Office worker
- **Chief Complaint:** "My big toe has been hurting and looks more crooked."
- **History:**
 - Onset: Gradual worsening over 2 years.
 - Pain: Located over the medial 1st MTP joint, worse with prolonged walking or tight shoes.
 - Shoes: Frequently wears heels with narrow toe boxes.
 - Previous Treatments: Tried over-the-counter bunion pads and wider shoes with limited relief.
 - Medical History: No diabetes or other systemic illnesses.
- **Clinical Findings:**
 - Hallux abducted with a visible medial prominence.
 - Tenderness over the medial eminence.
 - Reduced dorsiflexion of the 1st MTPJ.
 - Weight-bearing X-ray shows an intermetatarsal angle of 15°.

Quiz

Questions

for Wrap-Up



What is the intermetatarsal angle threshold for diagnosing Hallux Valgus?

- A) $>9^\circ$
- B) 15°
- C) 20°
- D) 25°



Name one non-surgical treatment option for Hallux Valgus.



True or False: Hallux Valgus is primarily caused by wearing high heels.



Which surgical procedure is suitable for severe hypermobility in the 1st Ray?