

Psoriatic Arthropathy

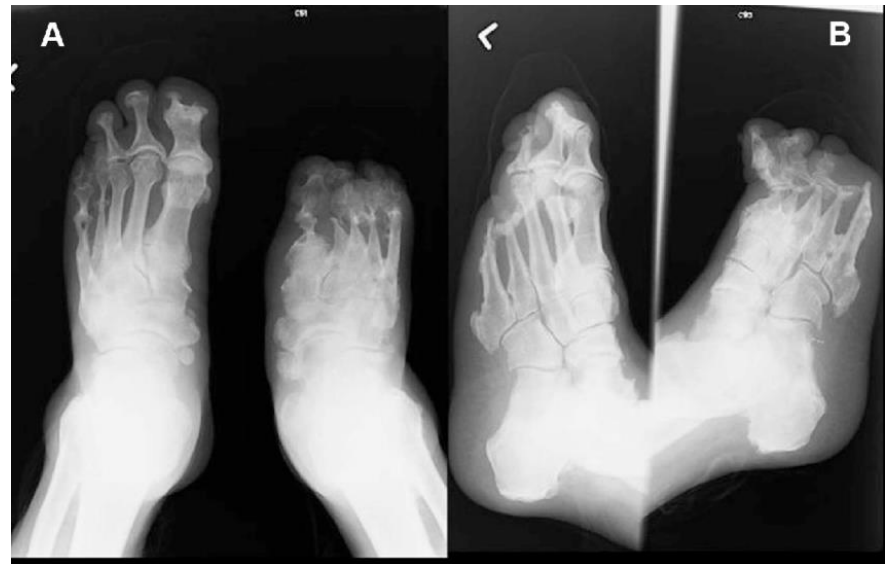

- Steve Kriss MPhil FRCPodS
- Consultant Podiatric Surgeon
- Royal College of Podiatry
- Liverpool 2023

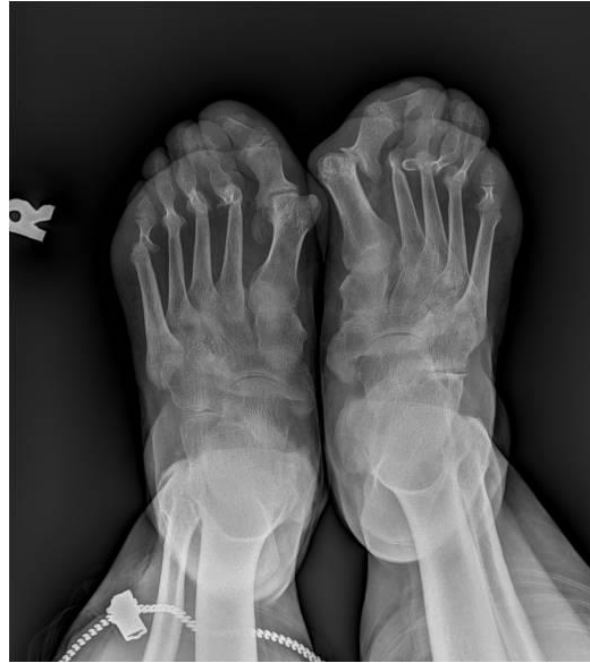

Ps Arthropathy Presentation

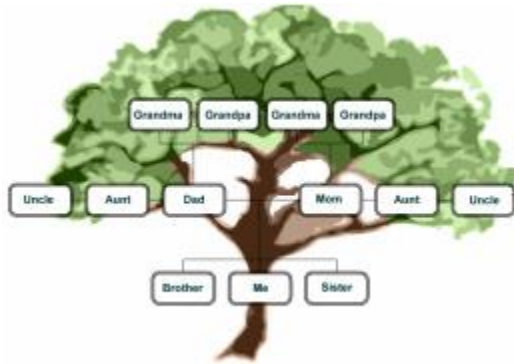- Distal Interphalangeal predominant
- Asymmetric Oligoarticular
- Symmetric Polyarthritits
- Spondylitis
- Arthritis Mutilans



Common Presentations



- Dactylitis
- Metatarsalgia
- Soft tissue pathology/Achilles/Haglunds



Its all in the History

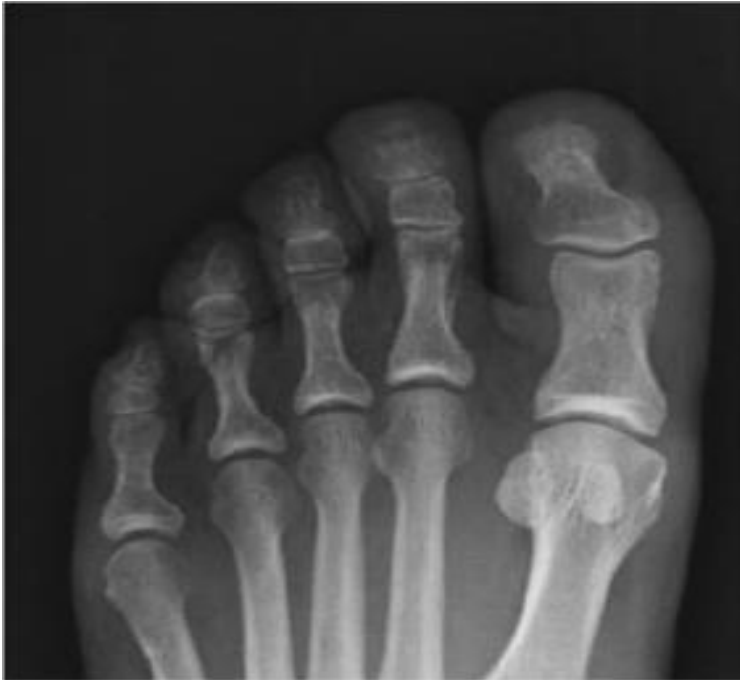- Pre existing or family history of Psoriasis
- Literature Suggests that about 20-30% of patients with Psoriasis develop Ps Arthropathy
- And about 16-49% of patients with PsA develop dactylitis
 - Gurjit S. Kaeley, Lihi Eder, Sibel Z. Aydin, Marwin Gutierrez, Catherine Bakewell,
 - Dactylitis: A hallmark of psoriatic arthritis,
 - Seminars in Arthritis and Rheumatism,
 - Volume 48, Issue 2,
 - 2018,
 - Pages 263-273,
 - ISSN 0049-0172
- Often overlooked by other HCP

Bone and soft tissue changes

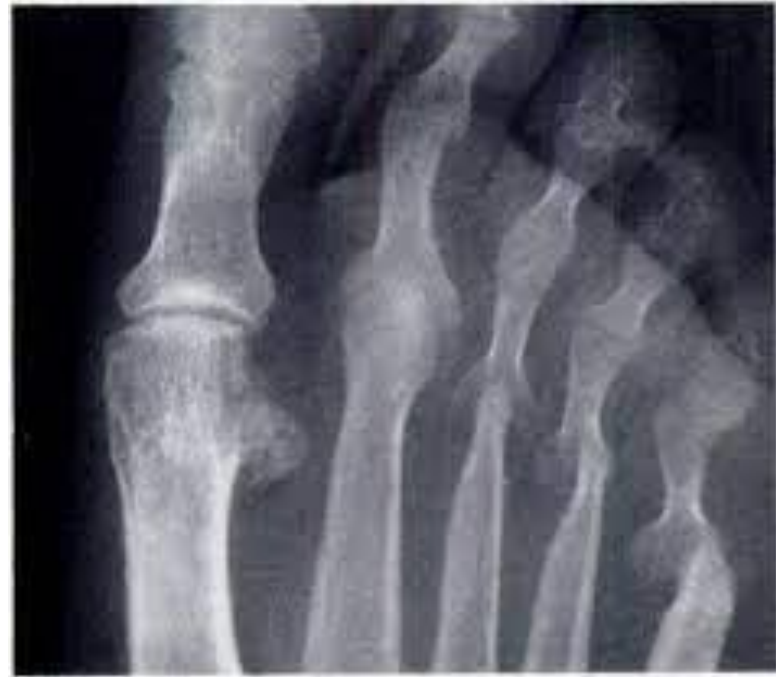- Tenosynovitis
- Extra-articular bone osteoproliferation
- Intra-articular bone proliferation
- Bone marrow oedema and joint space narrowing
- Erosion
- Soft-tissue oedema/thickening
- Effusion
- Plantar plate abnormalities
- Collateral ligament abnormalities
- Vascular changes
- Nail bed/matrix/plate abnormalities
- Tendon thickening
- Joint synovitis

Imaging

Early changes



Late Changes



Imaging

Ultrasound

- Girolimetto N, Macchioni P, Possemato N, Tinazzi I, Bascherini V, Citriniti G, McConnell R, Marchetta A, Peluso R, Sabbatino V, Salvarani C, Scarpa R, Costa L, Caso F.
- Musculoskeletal Ultrasound in Monitoring Clinical Response to Treatment in Acute Symptomatic Psoriatic Dactylitis: Results from a Multicentre Prospective
- Observational Study. *J Clin Med.* 2020 Sep 27;9(10):3127. doi: 10.3390/jcm9103127. PMID: 32992634; PMCID: PMC7601129.

• MRI

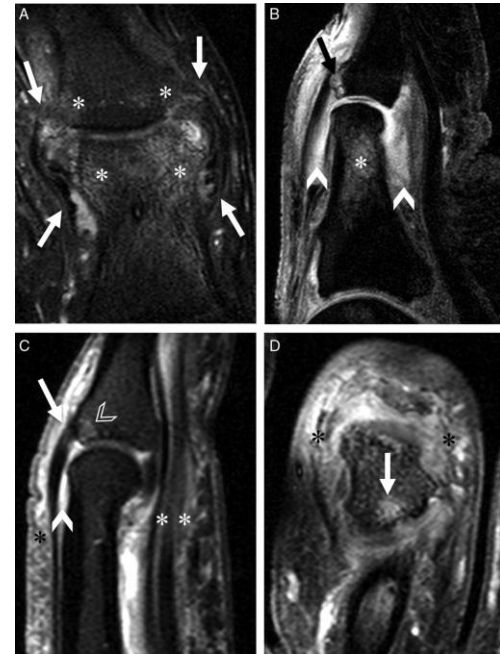
- Tan AL, Fukuba E, Halliday NA, *et al*
- High-resolution MRI assessment of dactylitis in psoriatic arthritis shows flexor tendon pulley and sheath-related enthesitis
- *Annals of the Rheumatic Diseases* 2015;**74**:185-189.

- Synovitis and soft-tissue oedema present in 69% of tender dactylitic digits
- Bone oedema and flexor tenosynovitis
- Soft-tissue oedema not limited to association with the flexor or extensor tendons.

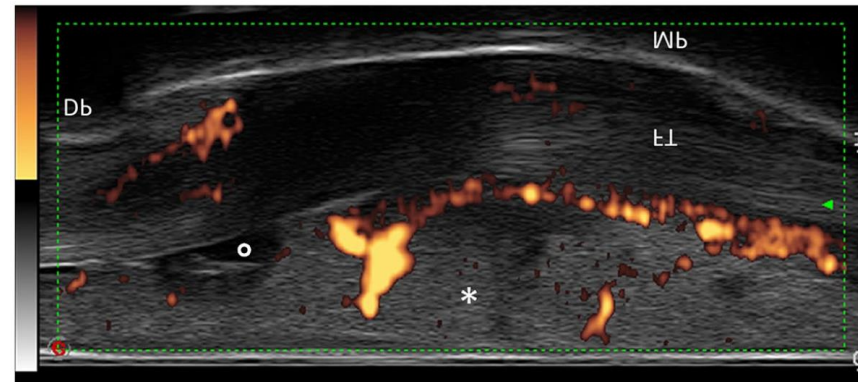
Imaging

MRI

- Bilateral collateral ligament enhancement
- Bone Marrow enhancement
- Bone marrow oedema

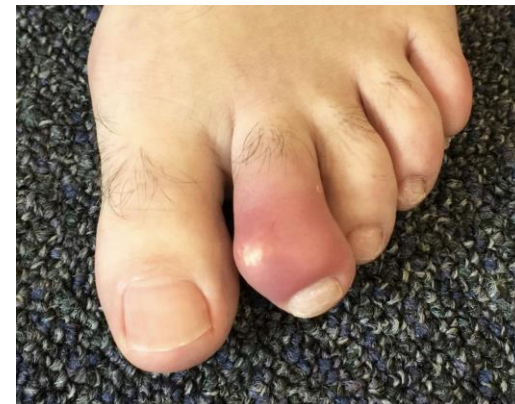
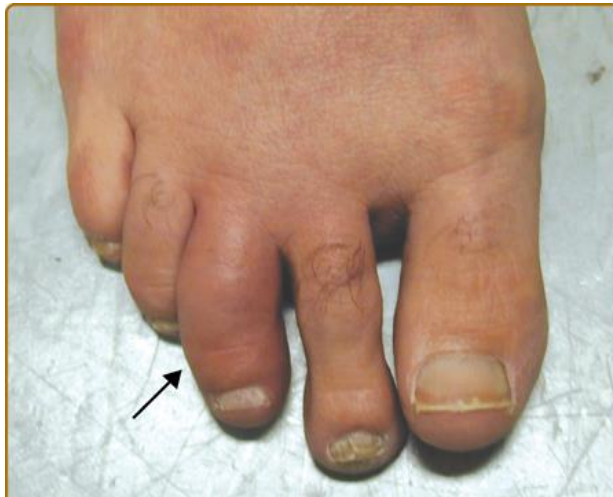
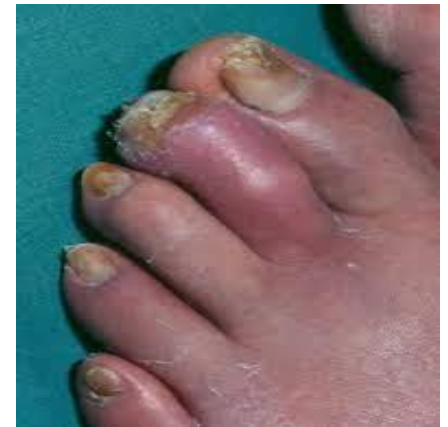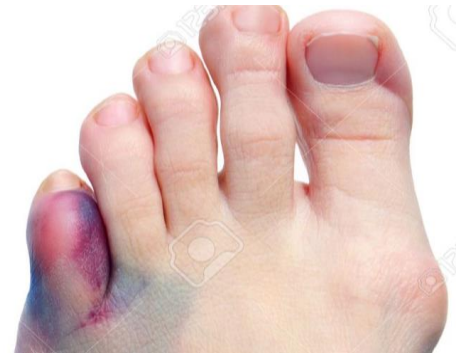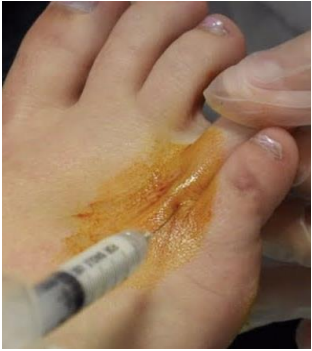- Ultrasound
- Tenosynovitis
- Synovial proliferation



Dactylitis

- Swelling of a digit
- Multiple causes
- Trauma/ Infection/ Gout



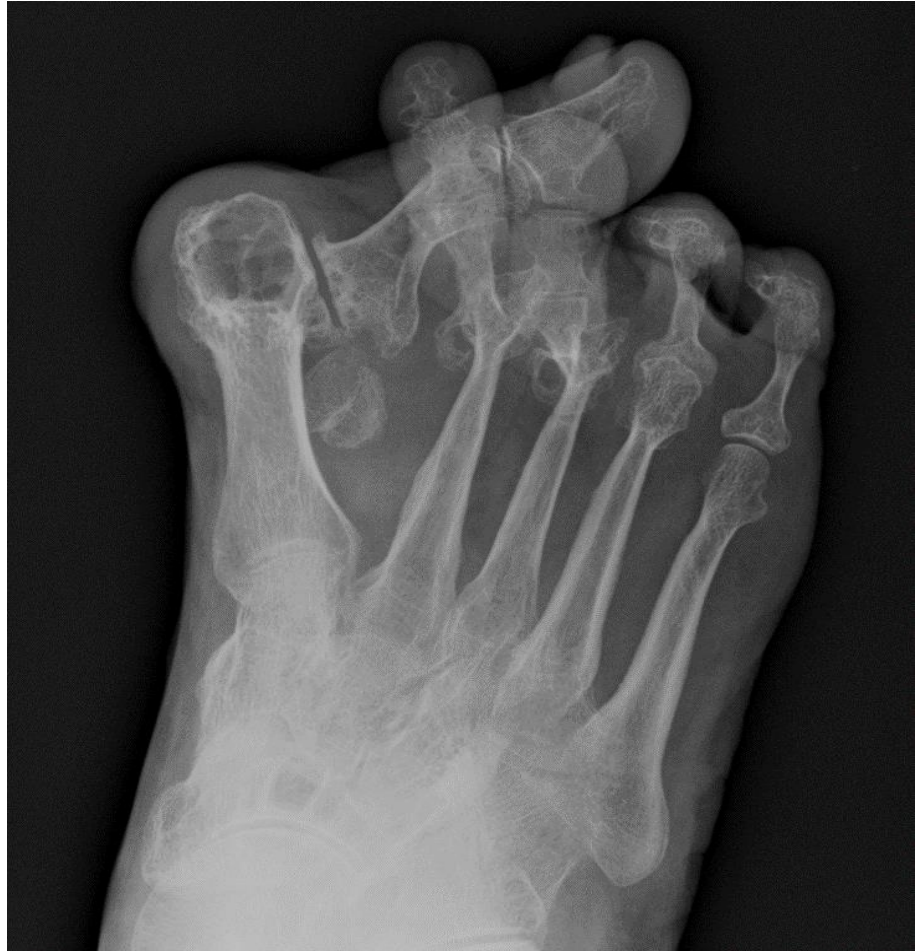

Treatment Systemic/Local

- Girolimetto N, Macchioni P, Citriniti G, Tinazzi I, Bascherini V, Martinis F, Marchetta A, Possemato N, Tasso M, Peluso R, Punzi L, Salvarani C, Scarpa R, McGonagle D, Costa L, Caso F.
- Effectiveness of steroid injection for hand psoriatic dactylitis: results from a multicentre prospective observational study.
- Clin Rheumatol. 2020 Nov;39(11):3383-3392. doi: 10.1007/s10067-020-05142-z. Epub 2020 May 16. PMID: 32418040.
- Conclusion
- For the first time, findings from this study show that the use of steroid injections into the digital flexor tendon sheath for psoriatic dactylitis could be an effective and safe first-line therapy for psoriatic dactylitis.

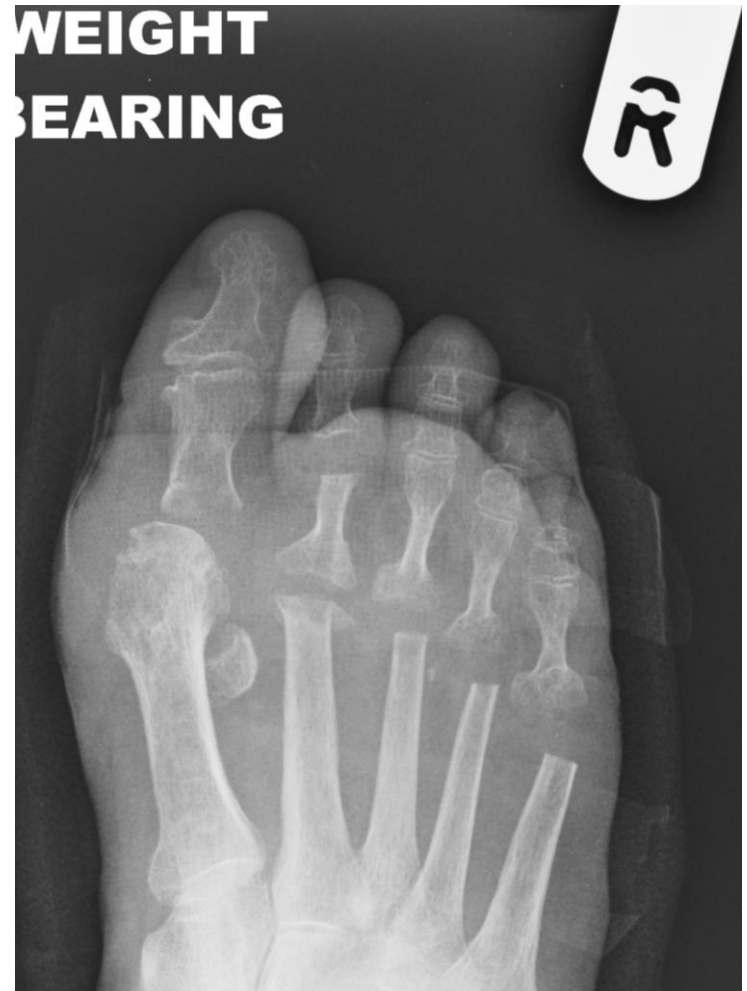
Metatarsalgia

- Joint Pain
- Plantar plate rupture
- Erosions
- Joint subluxation
- Digital deformity

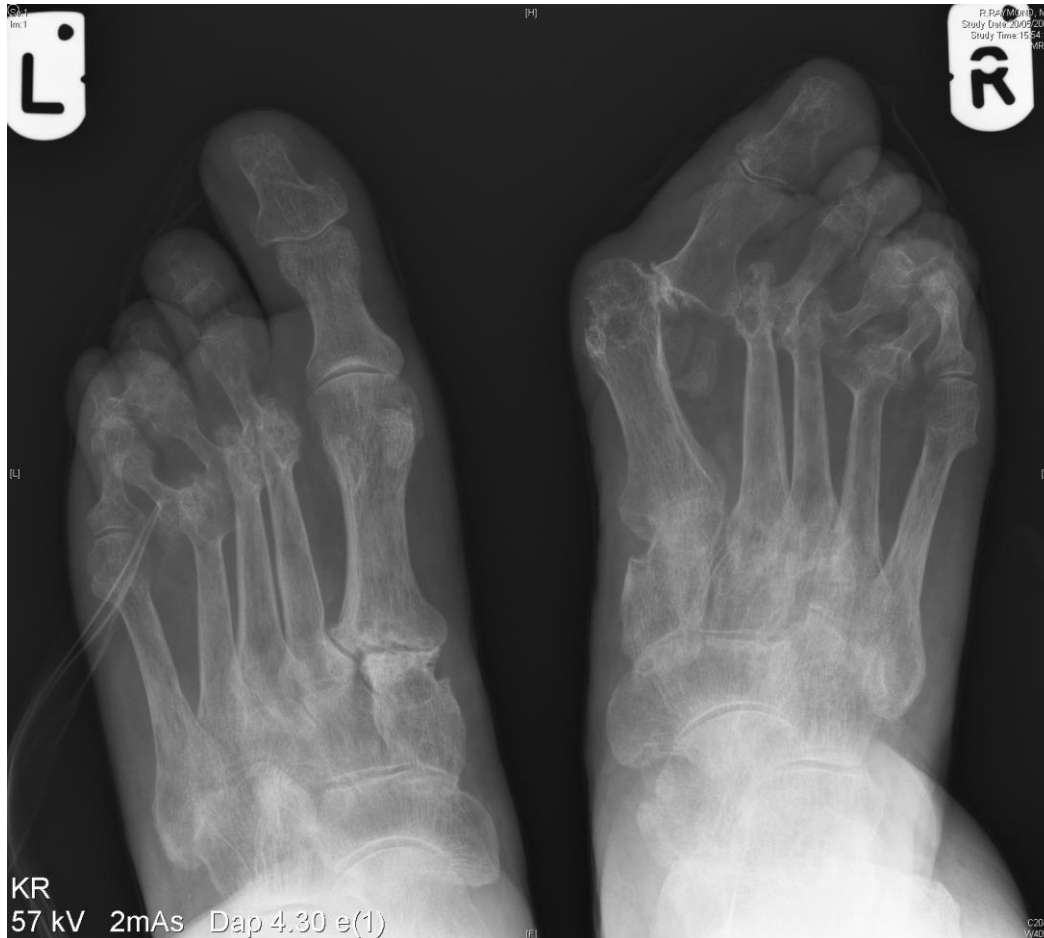

Metatarsalgia

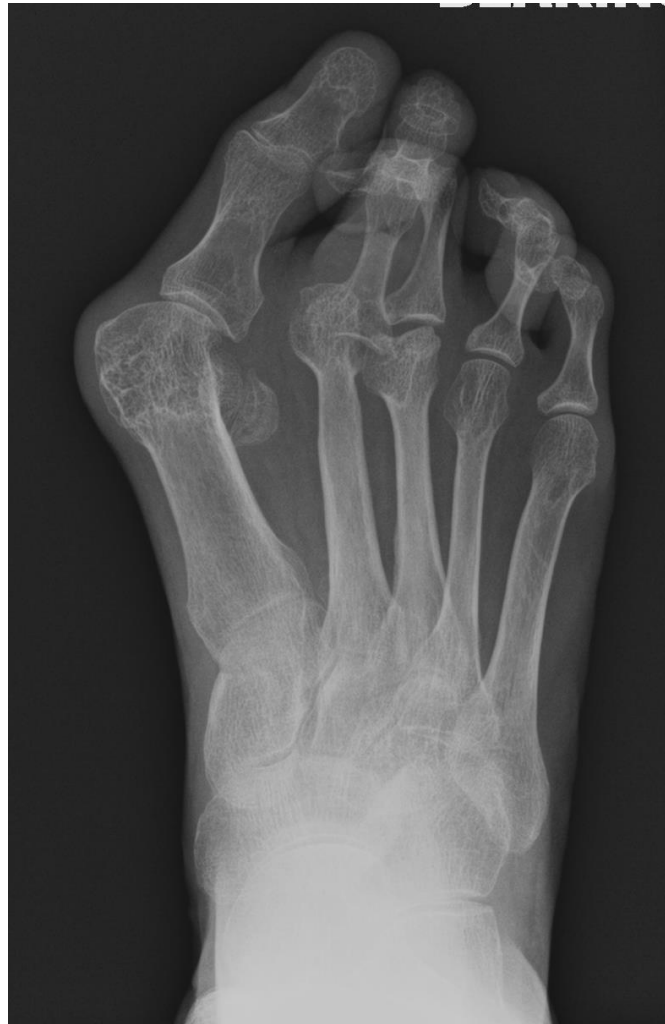- Joint pain from Ps Arthropathy
- Medical Management
- Surgical Options:
- Joint Sparing
- Joint destructive
- Helal
- Weil
- Schwartz
- Schweil
- Arthroplasty
- Single/Multiple Metatarsals
-



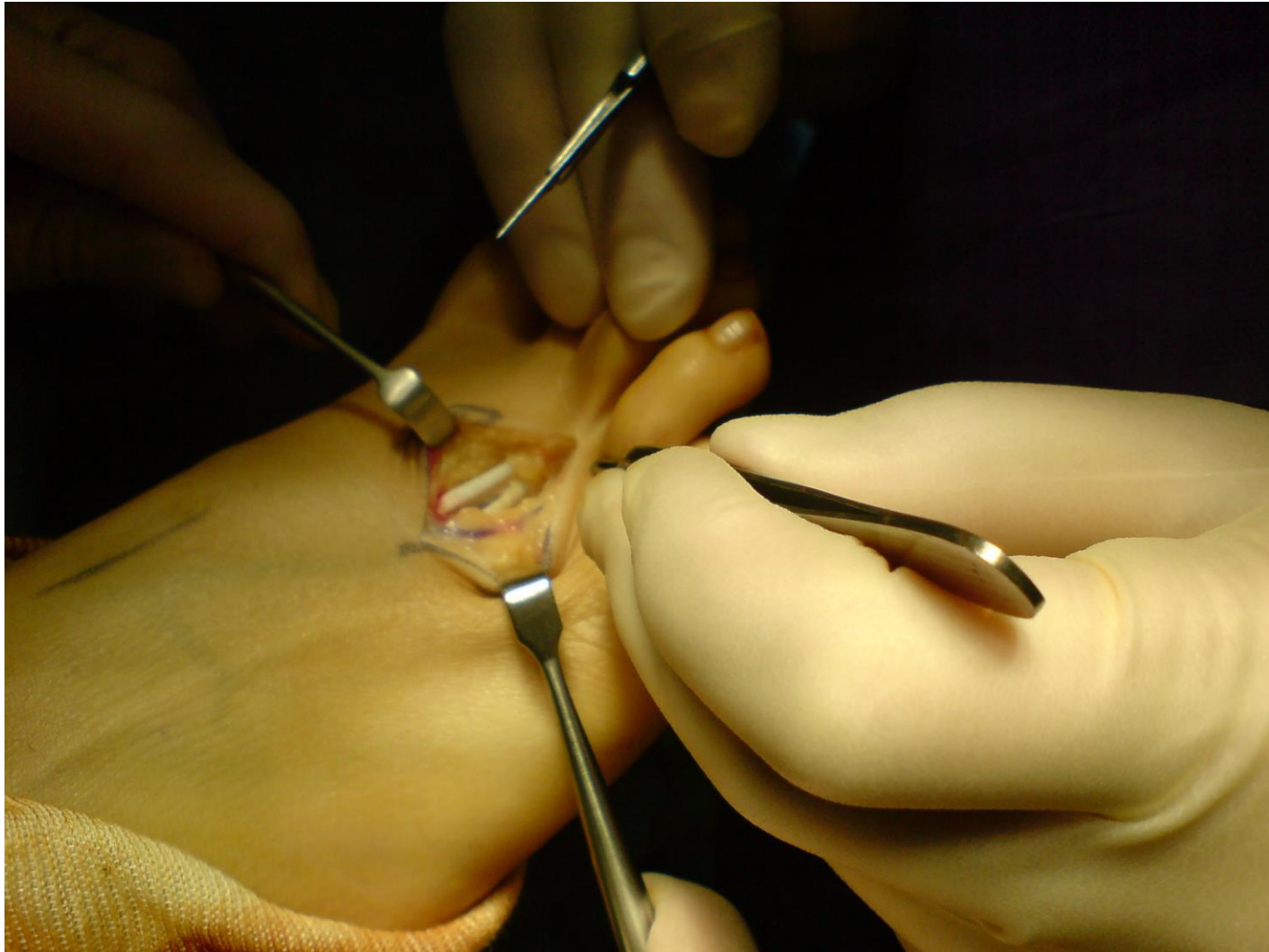Bone Quality



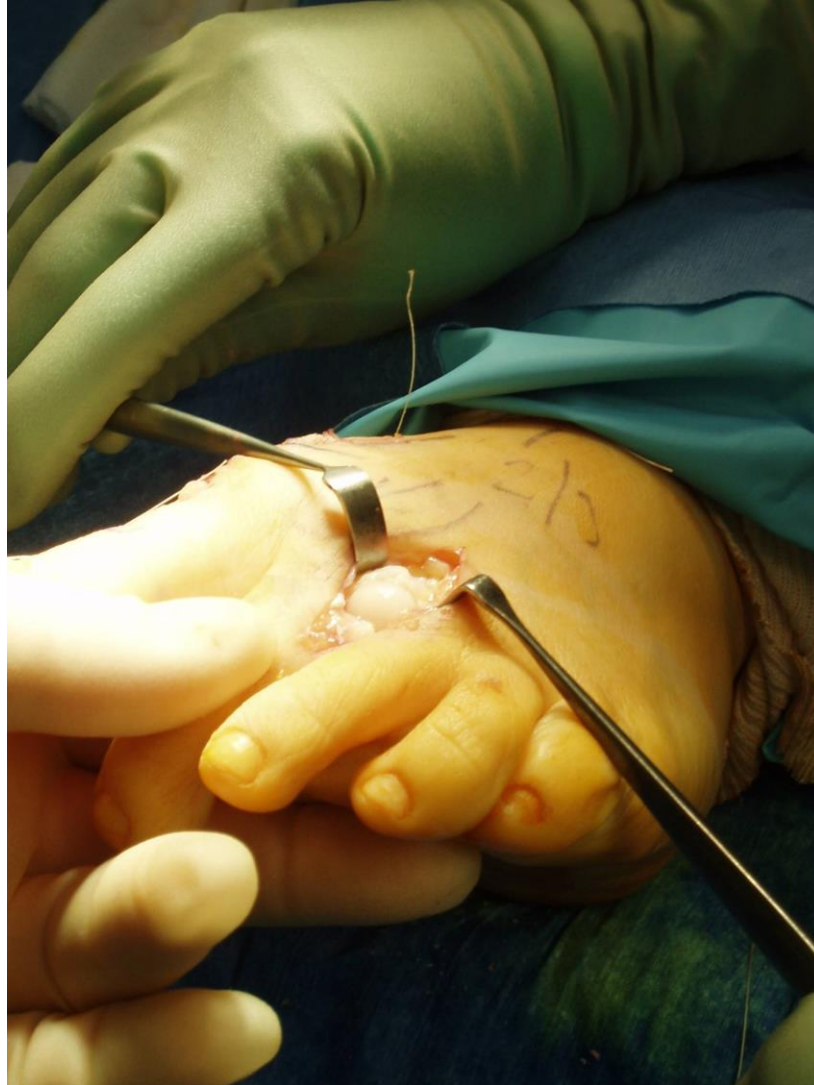Joint Subluxation



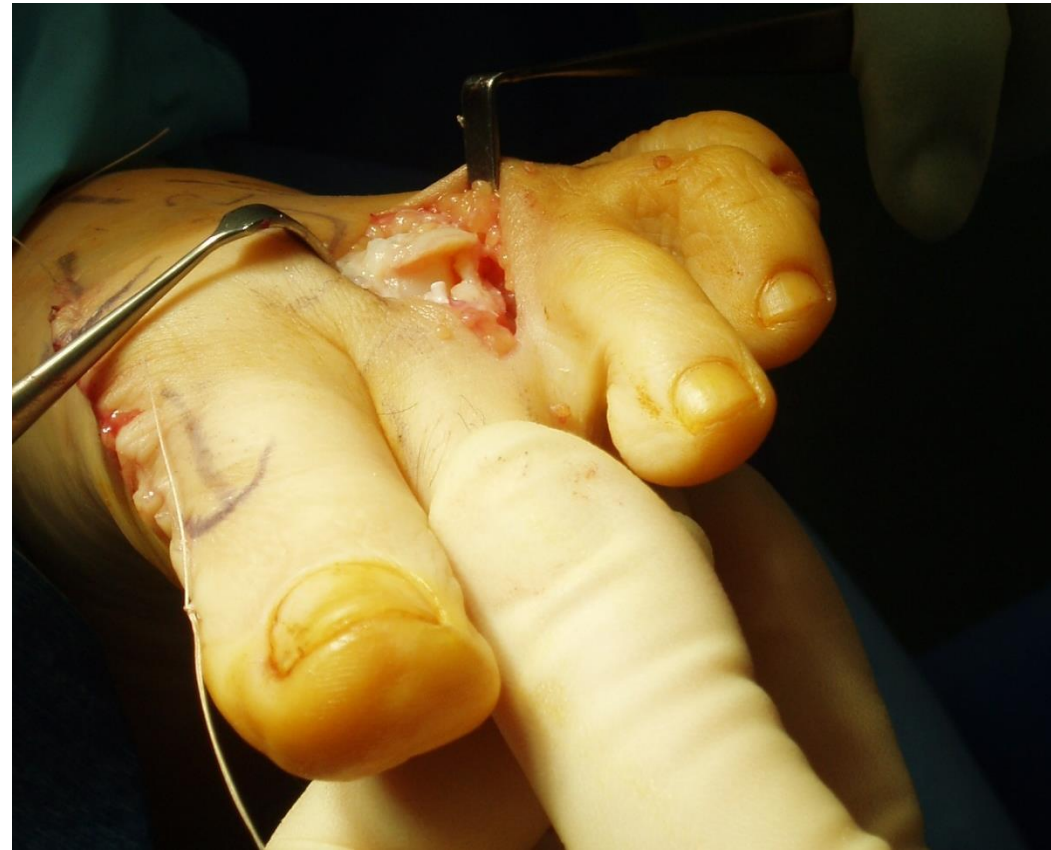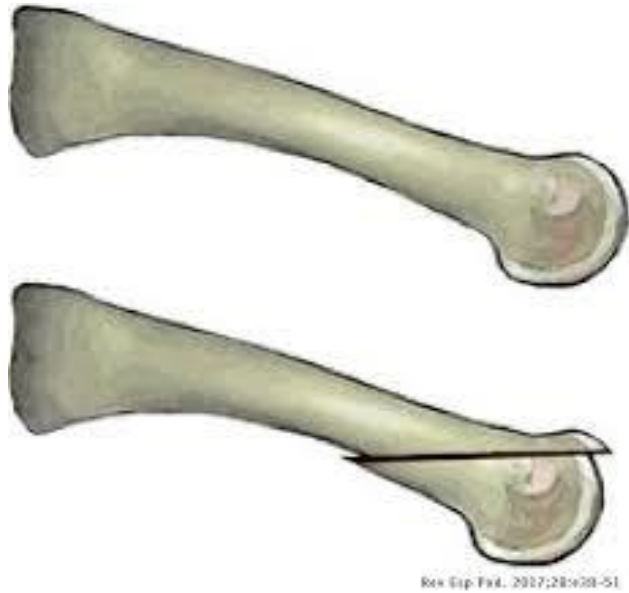
Weil Osteotomy



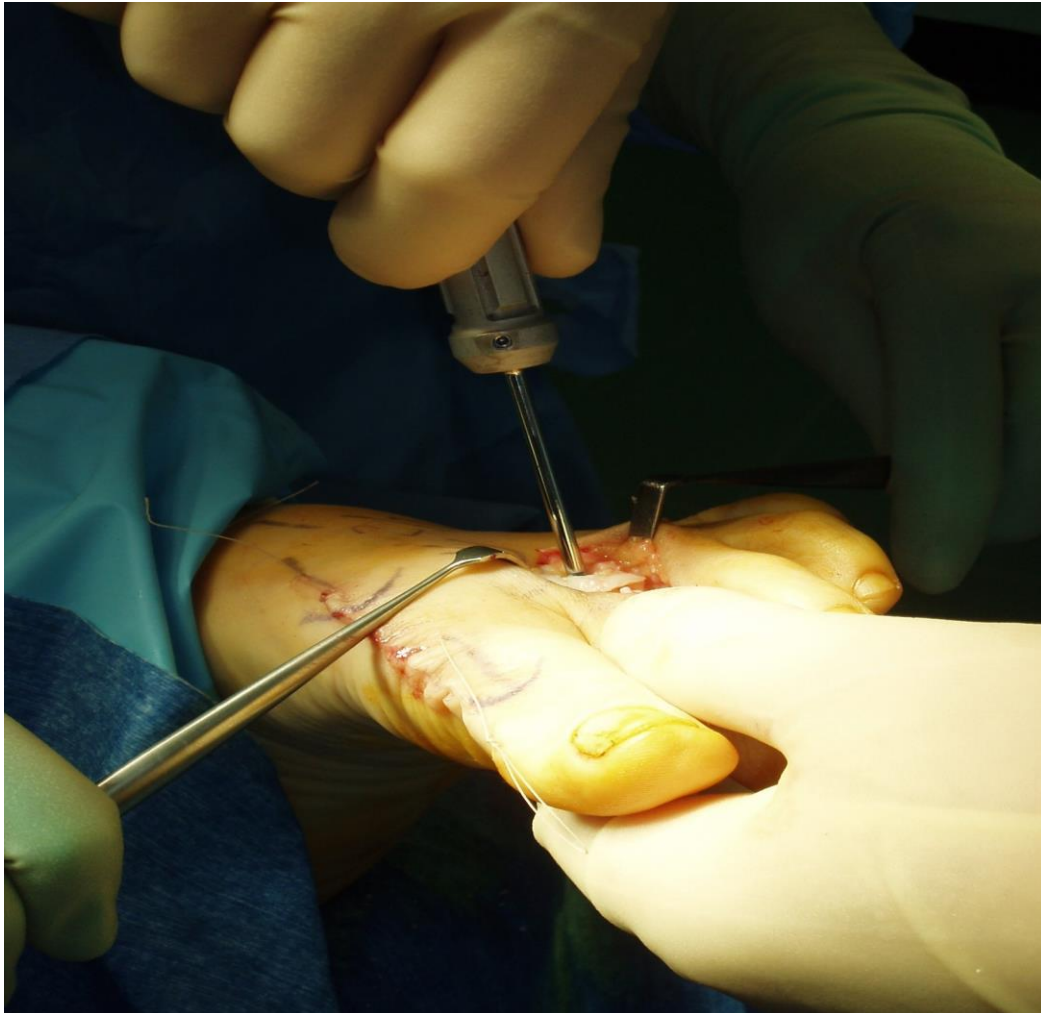
Expose the metatarsal head

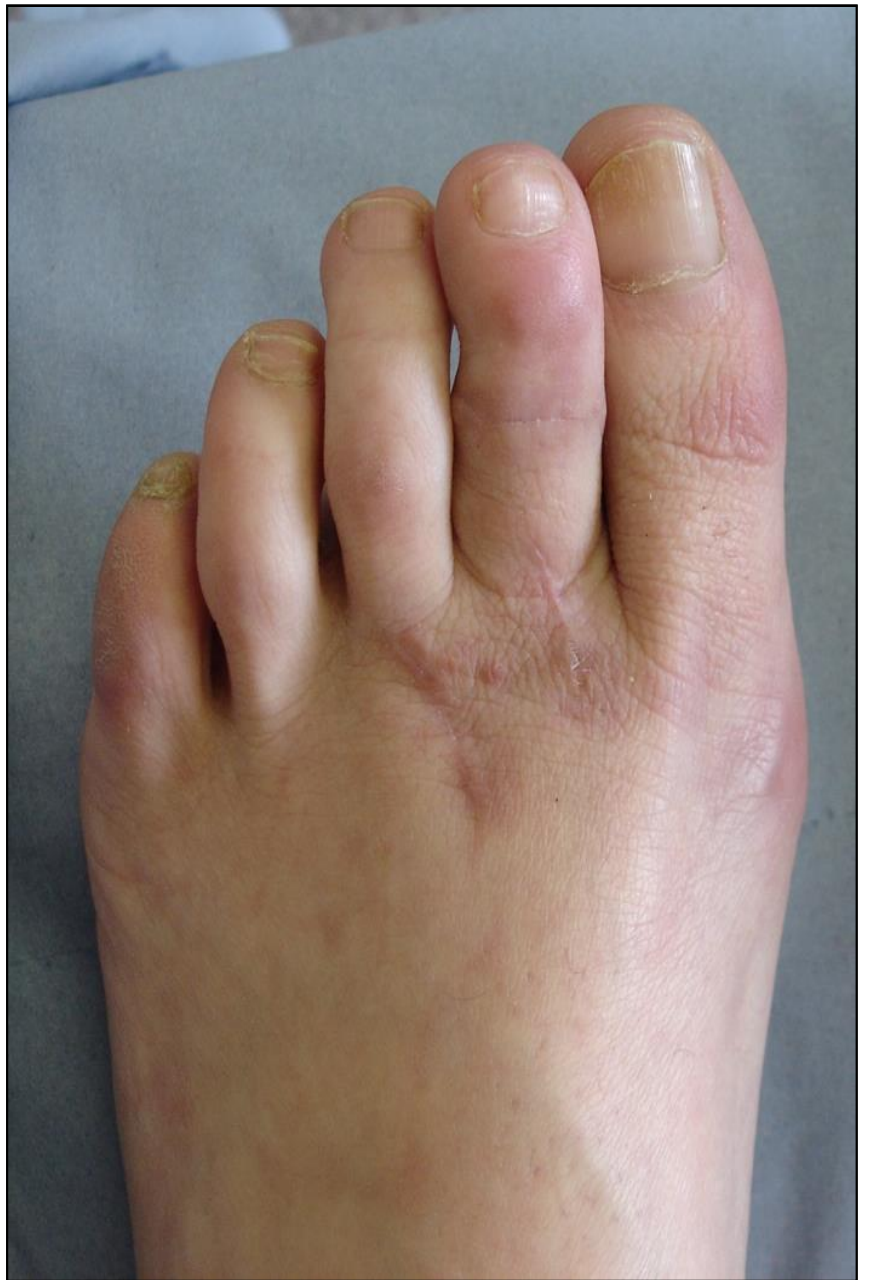
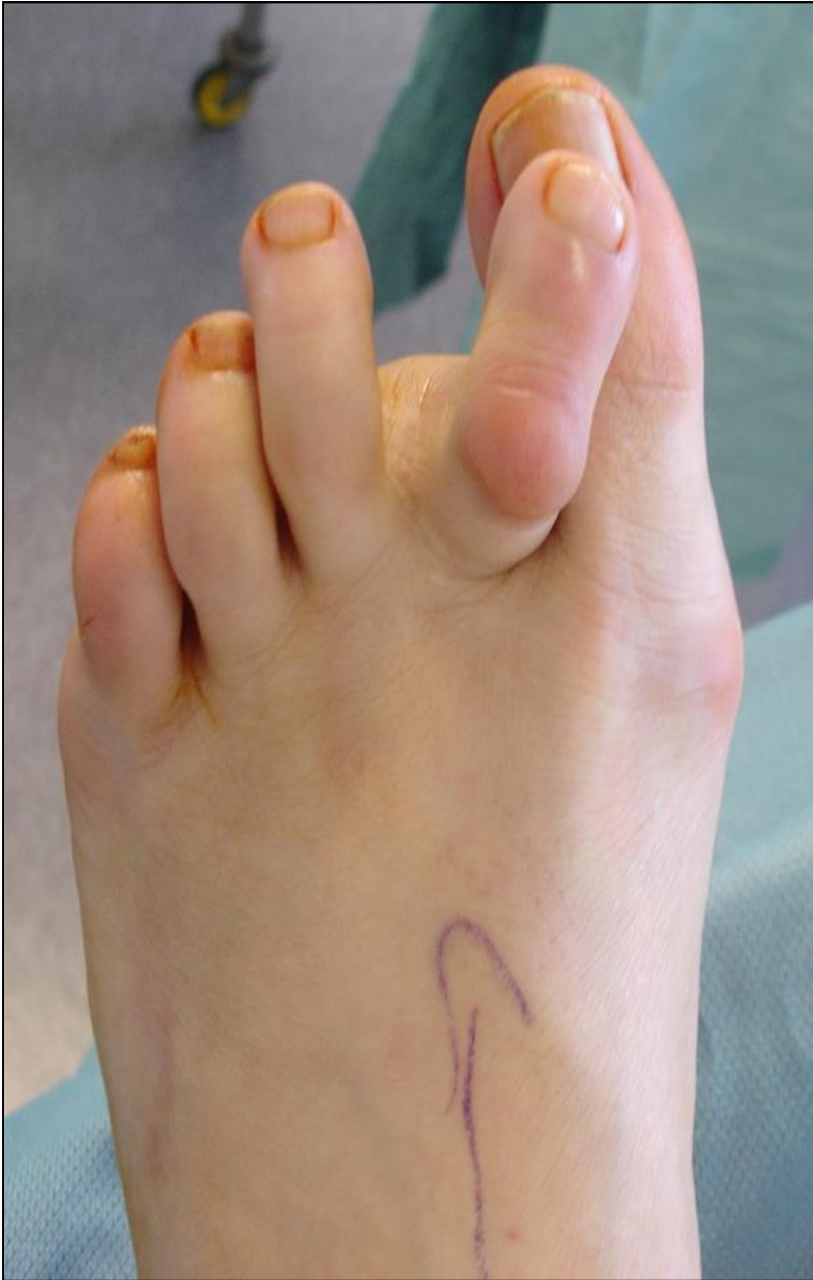
Proximally Displace Osteotomy

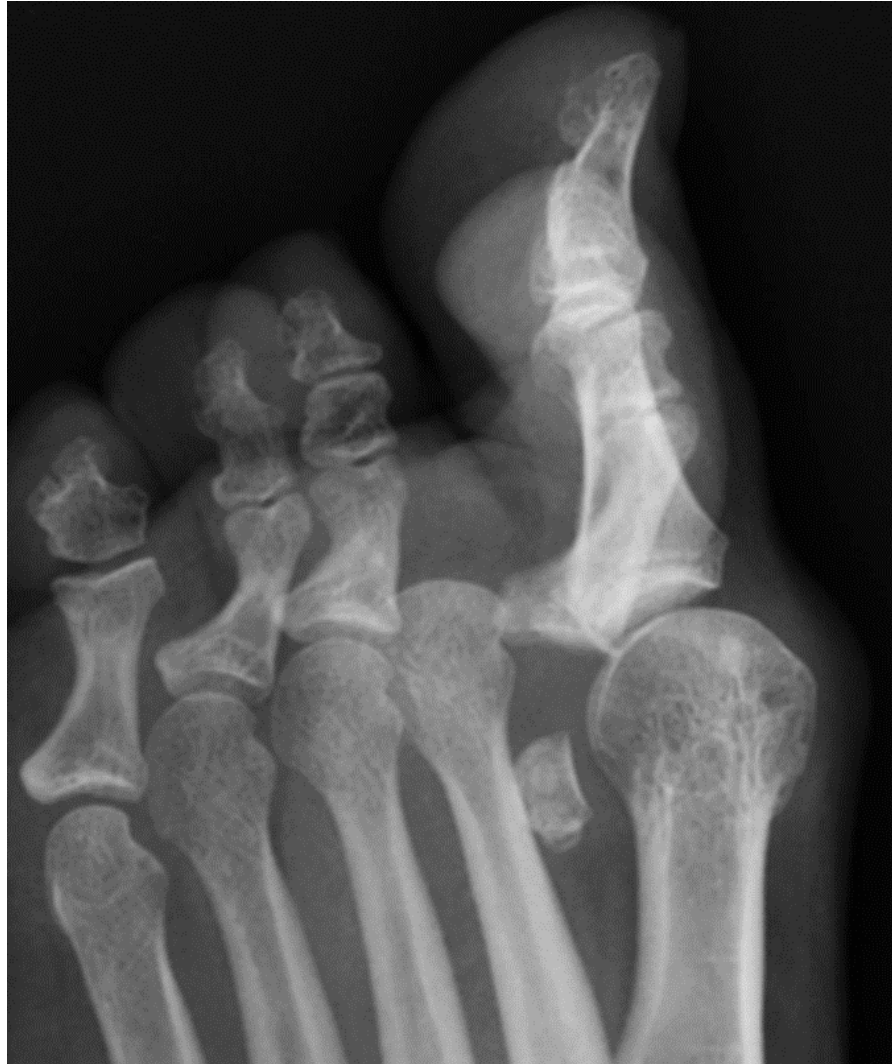

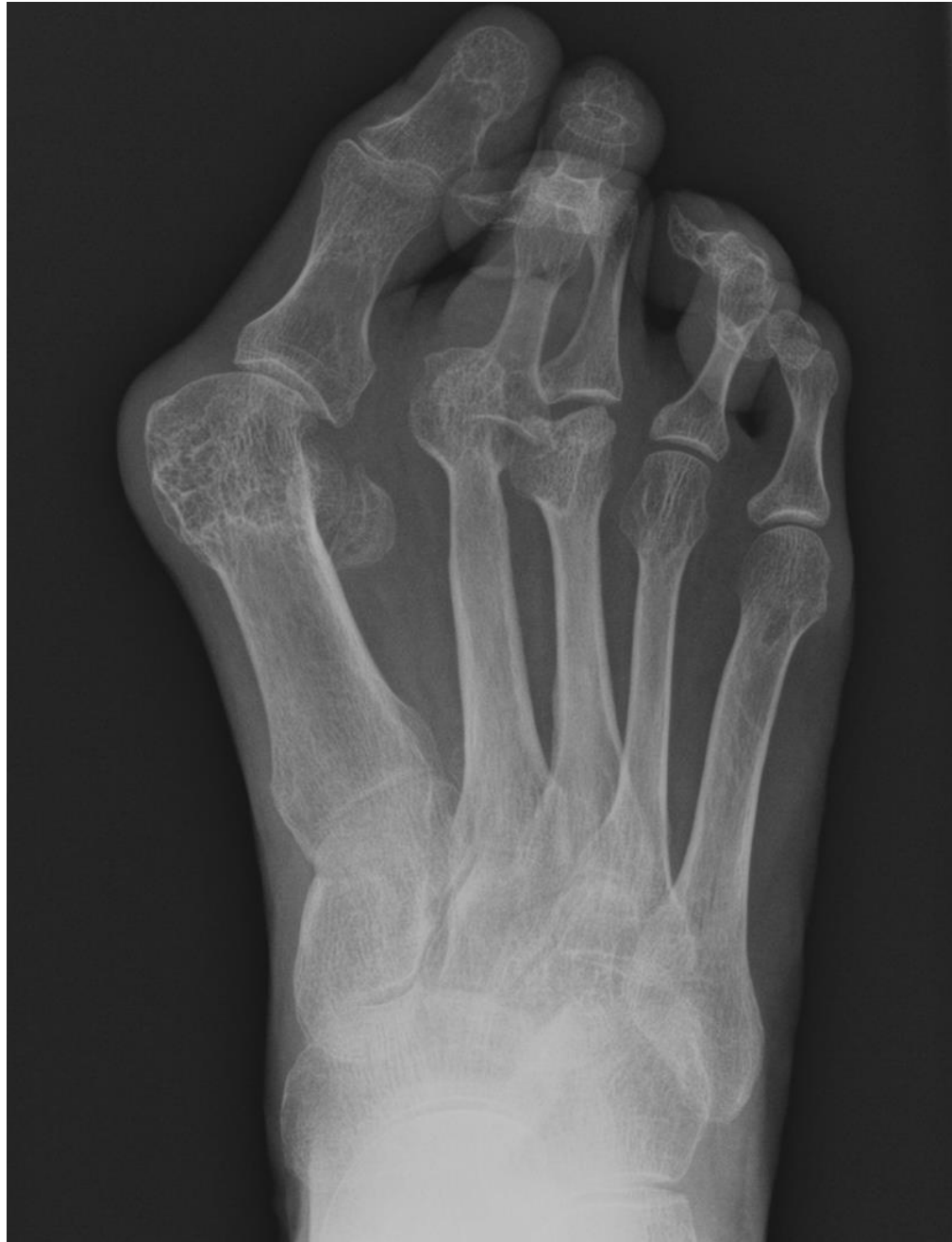Fixate

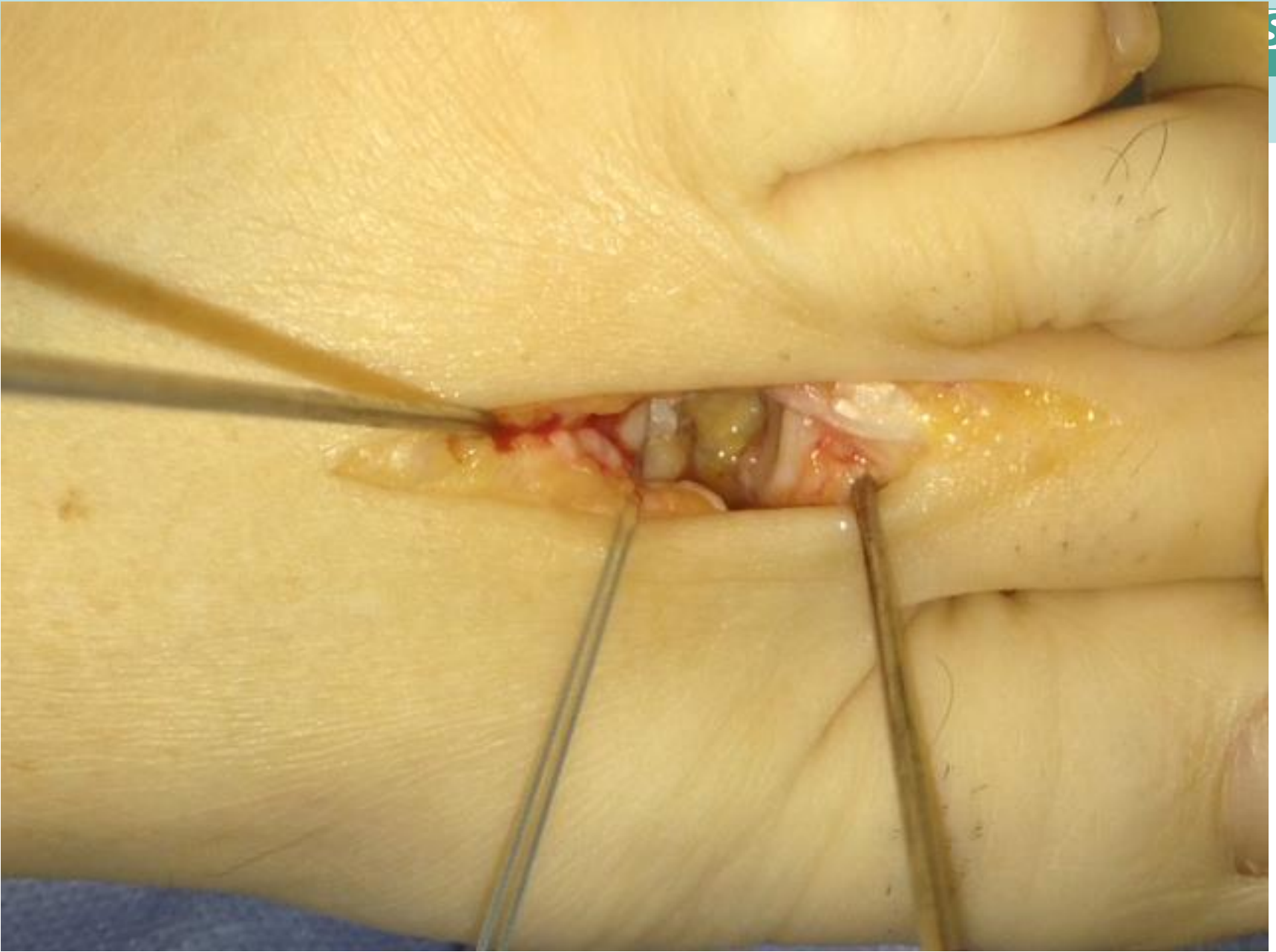

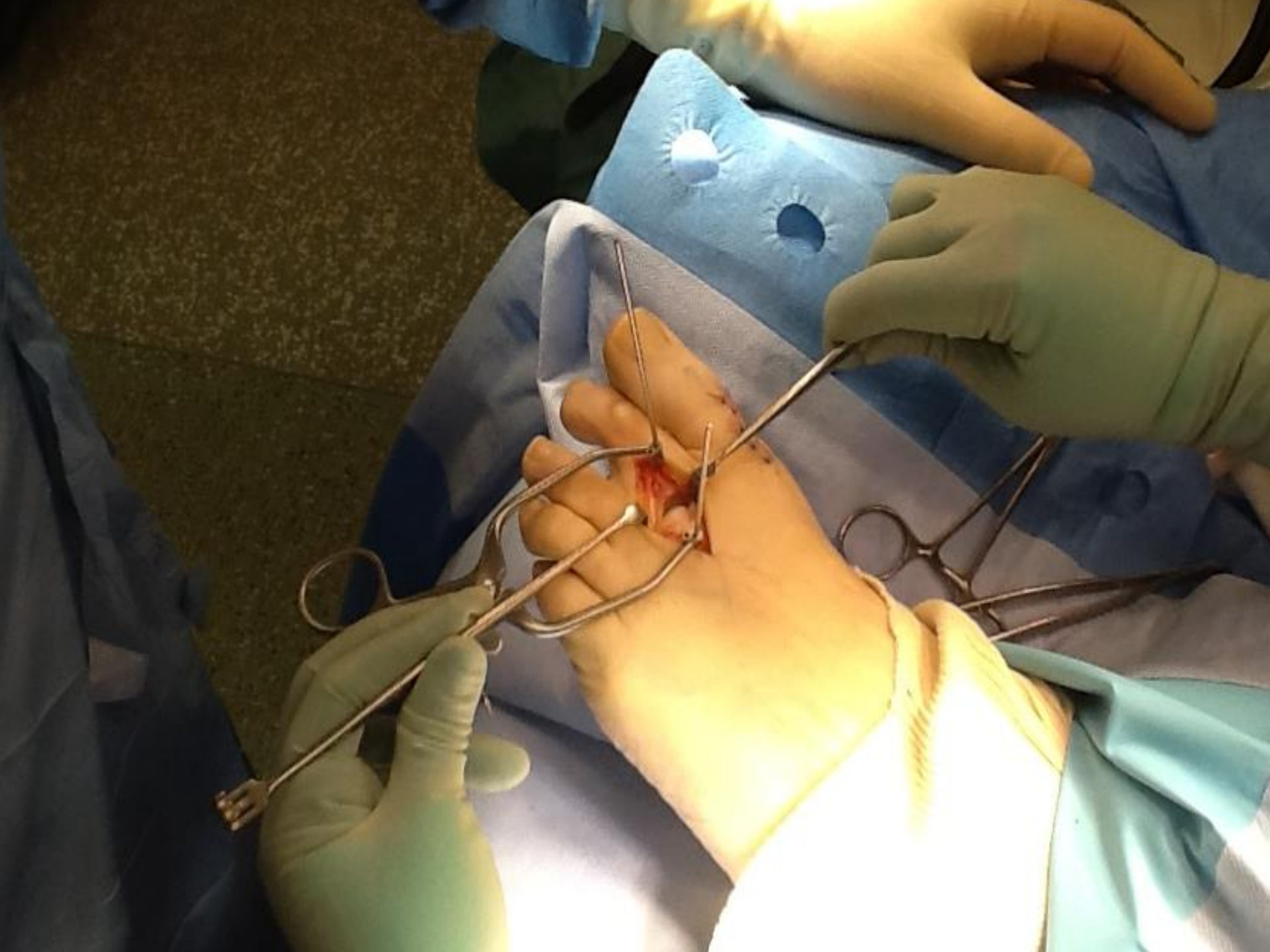


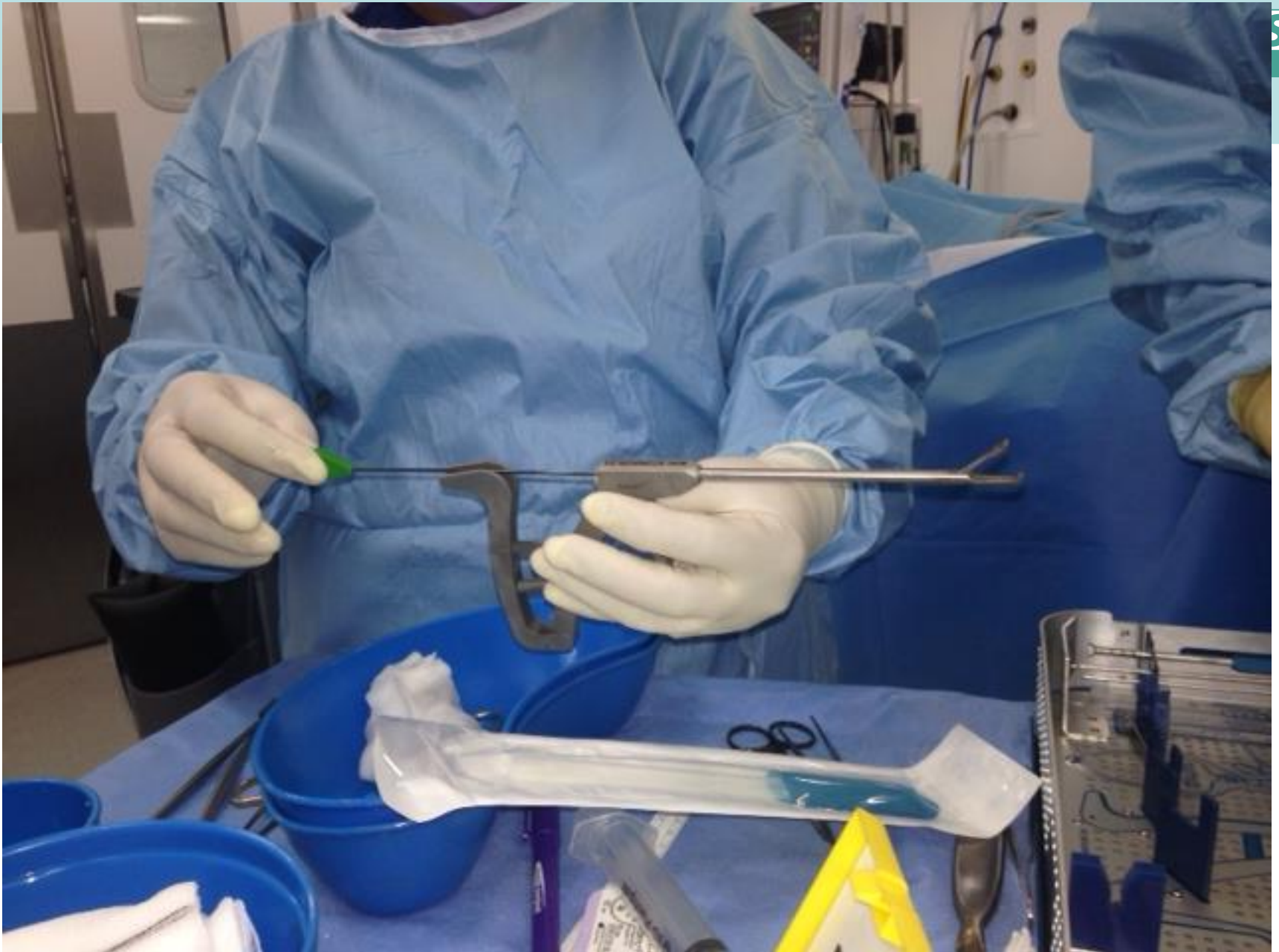
Subluxed joint



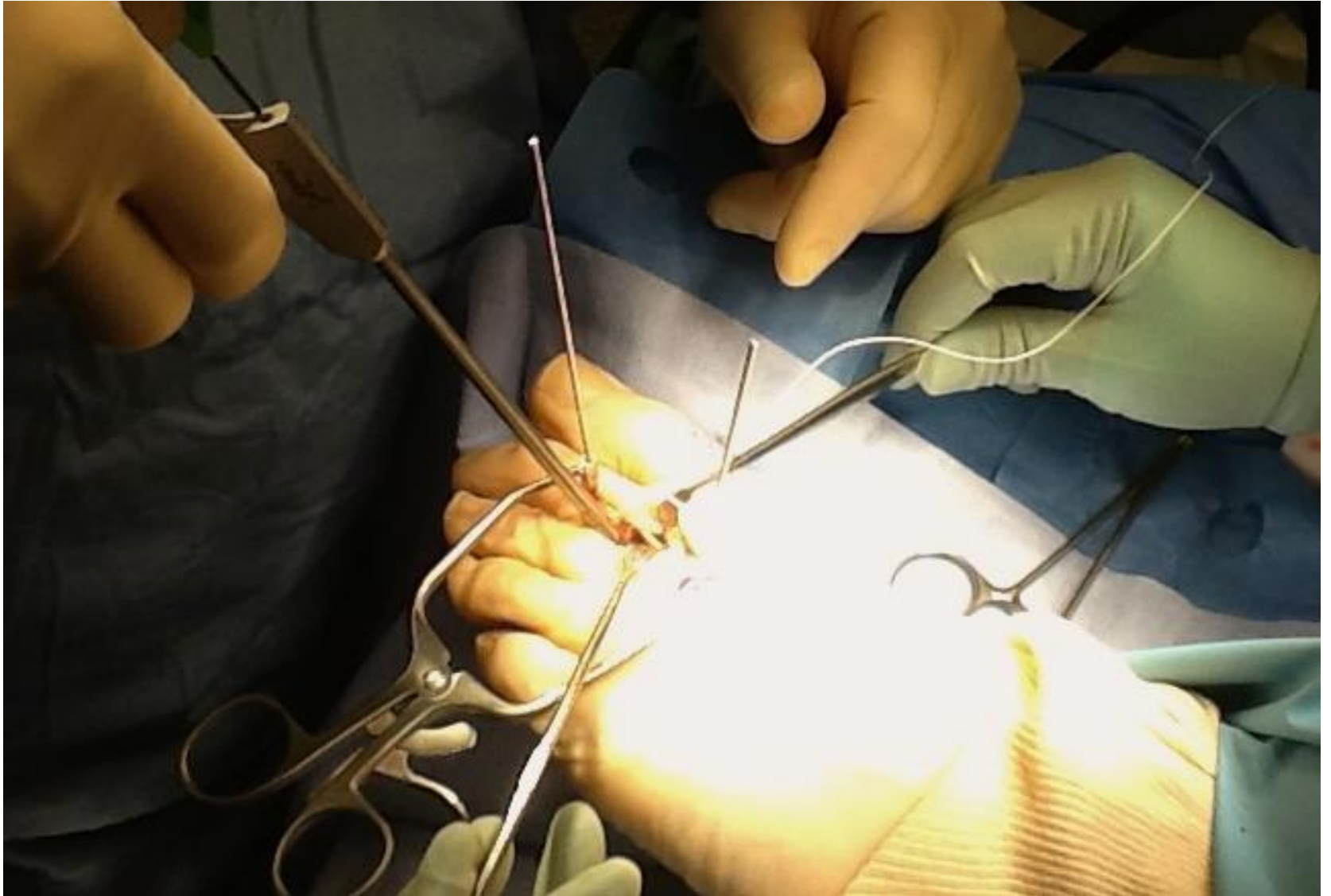


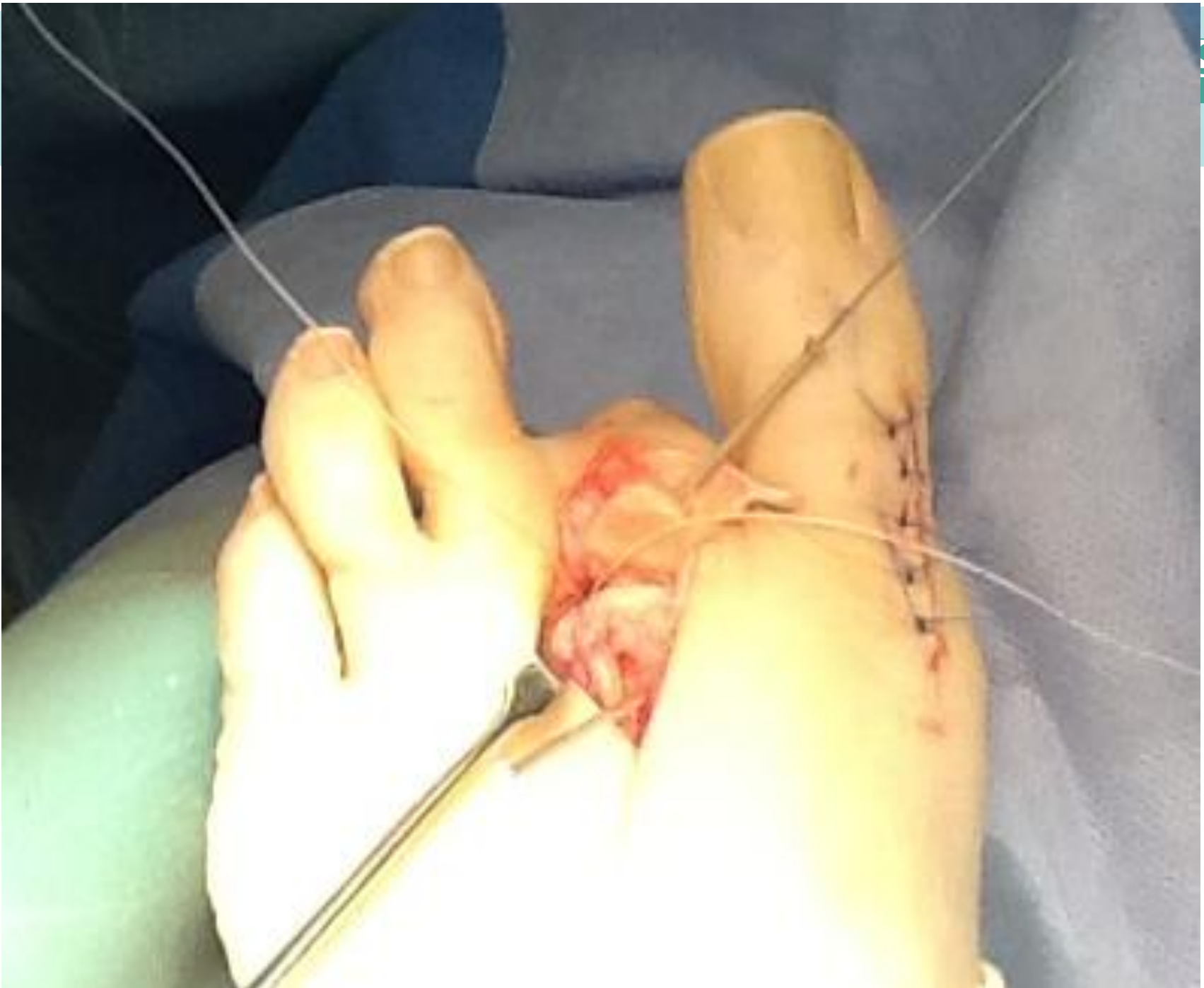




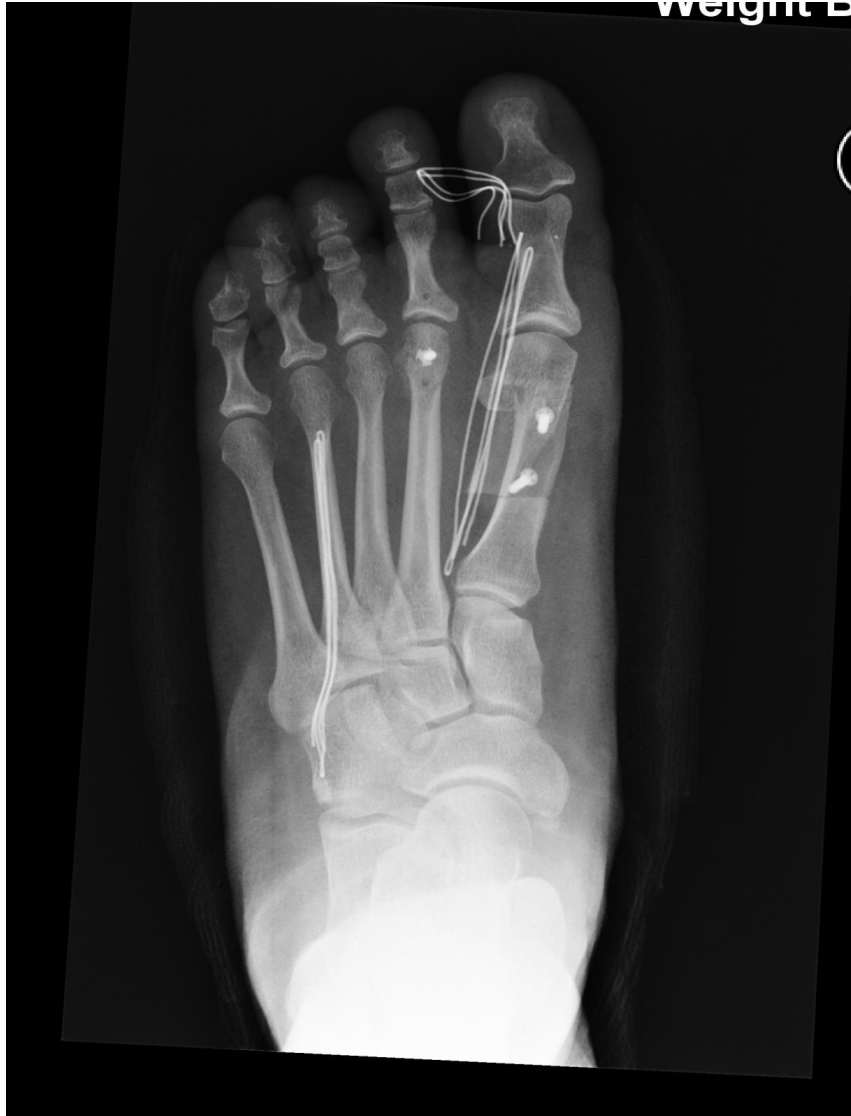
Reattach Flexor Tendon

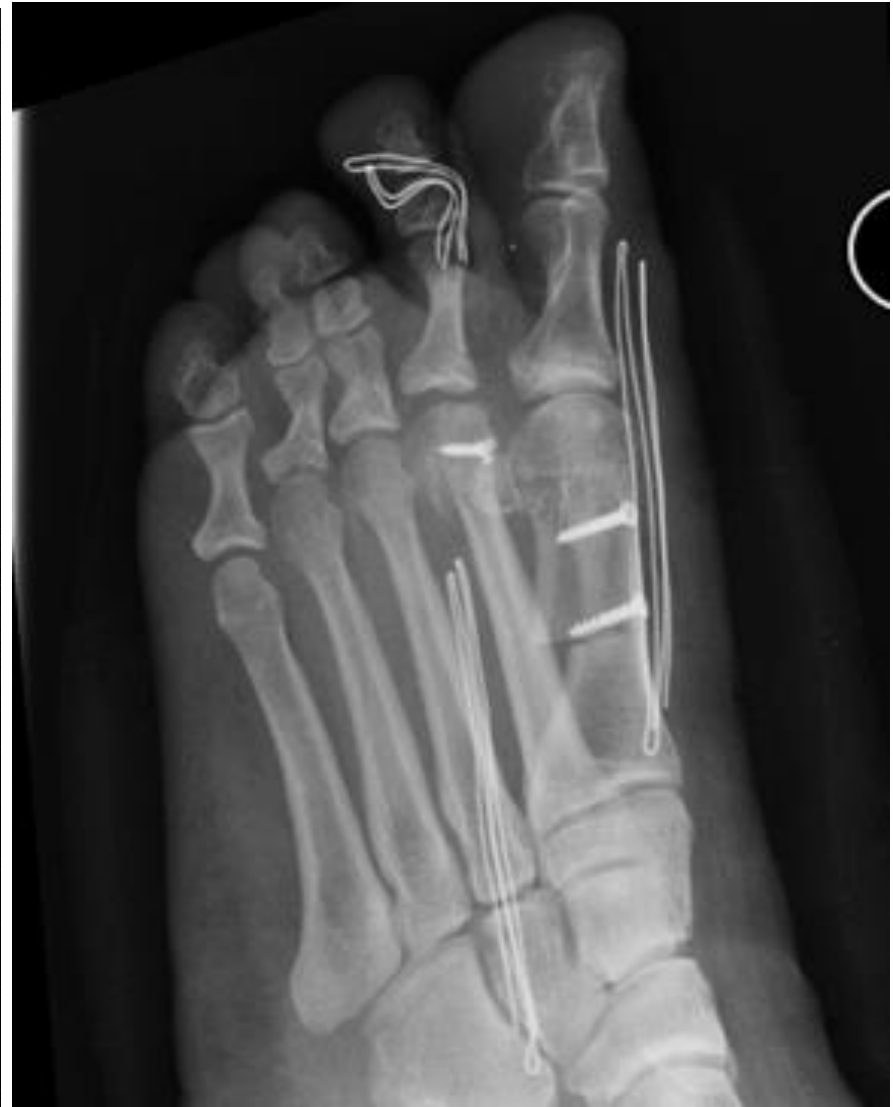
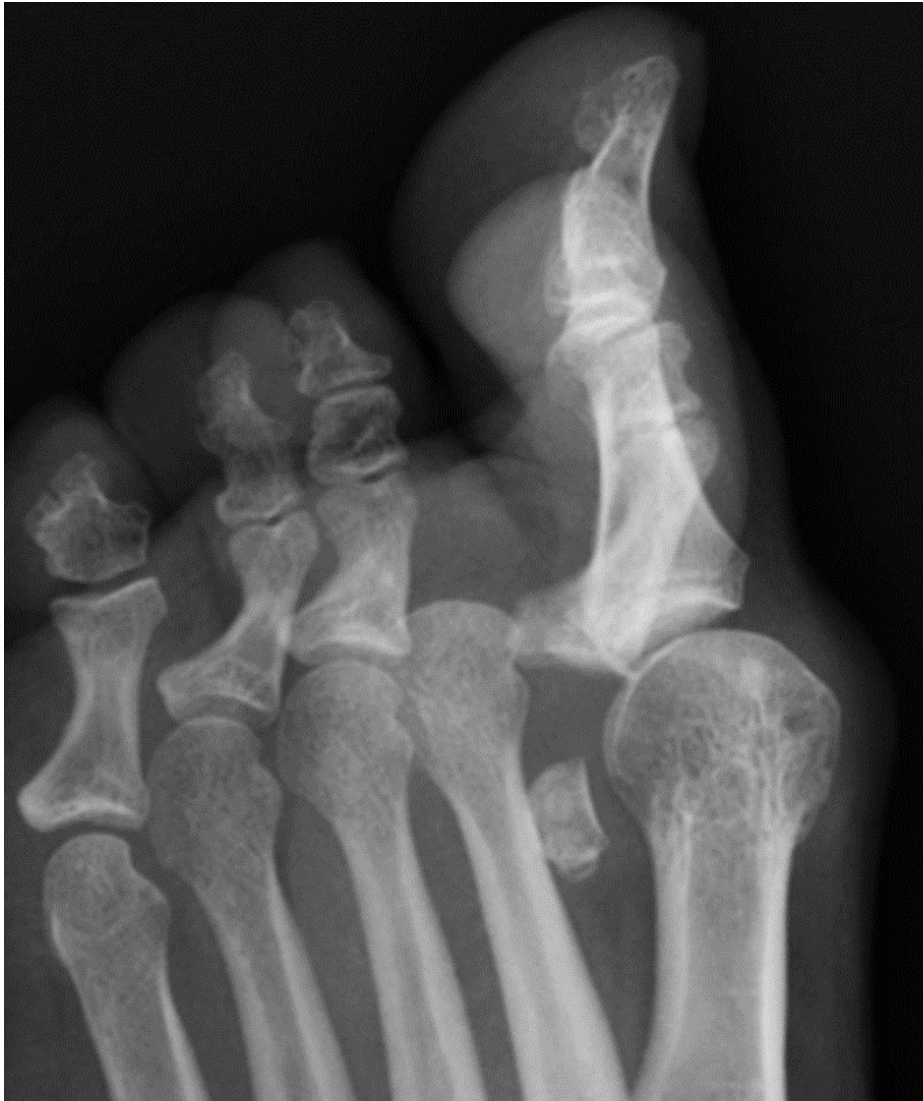


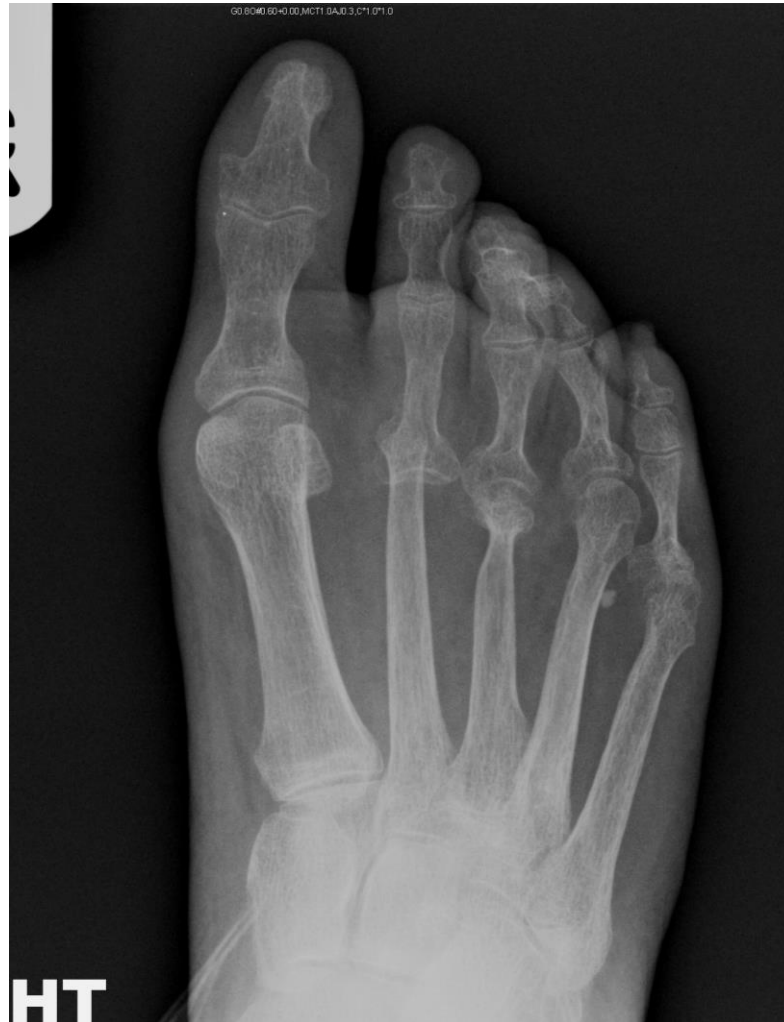weight B



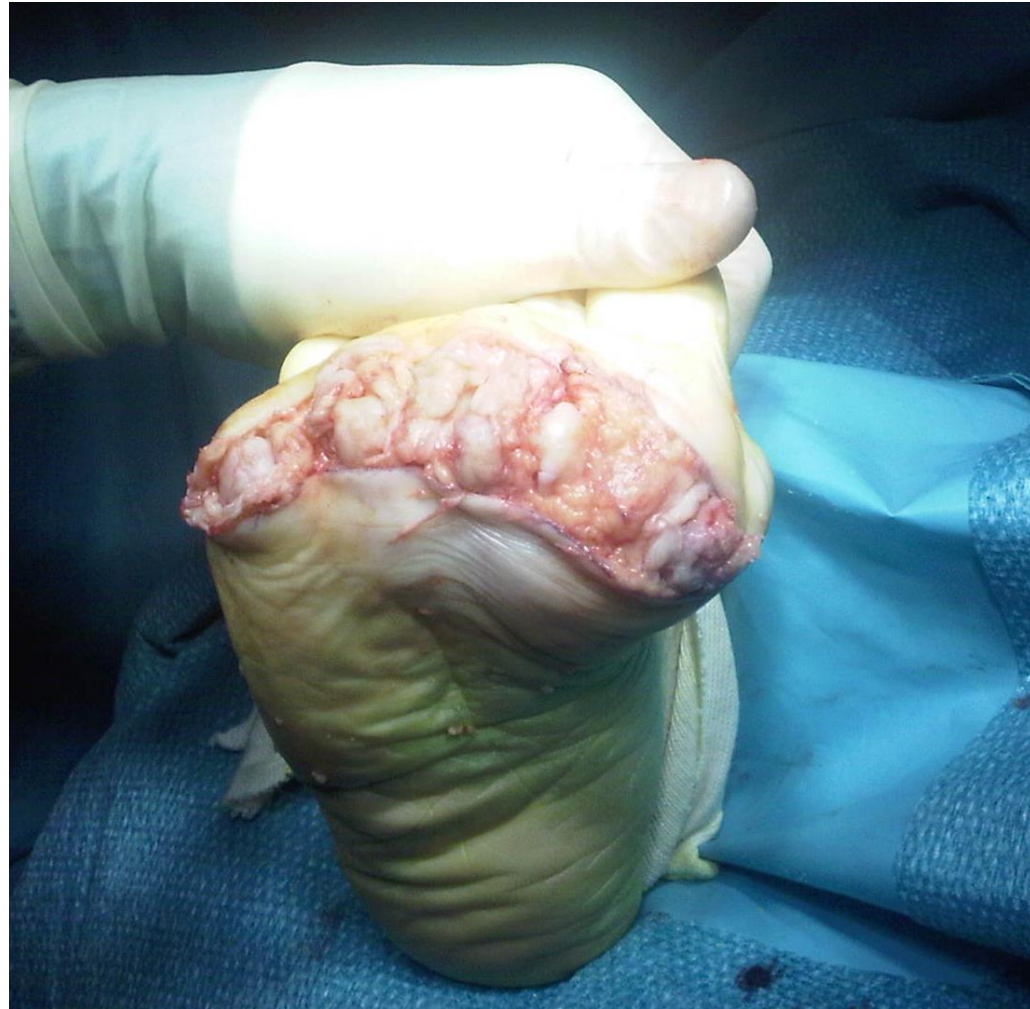
Before and After



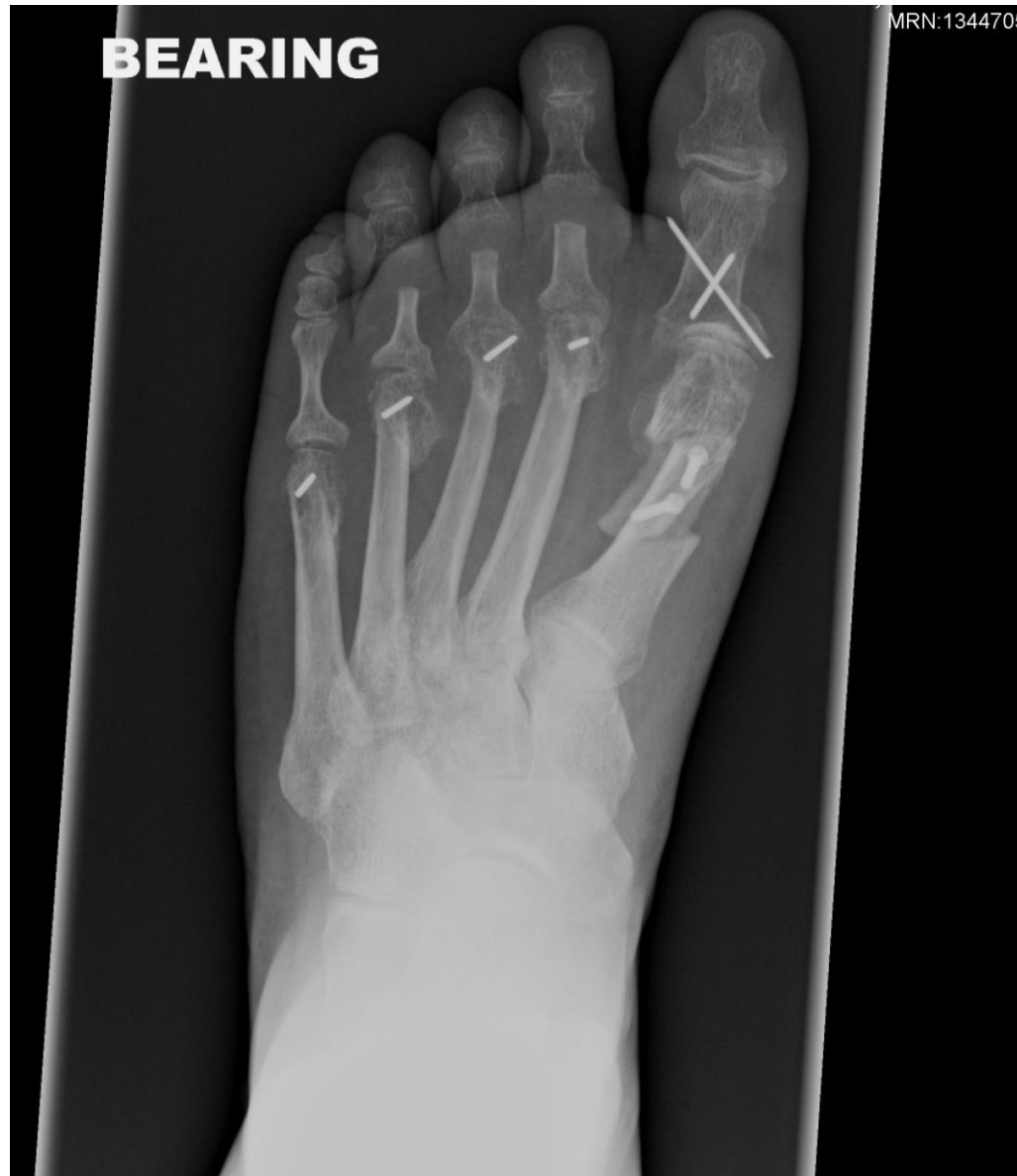Multiple subluxed joints with erosion



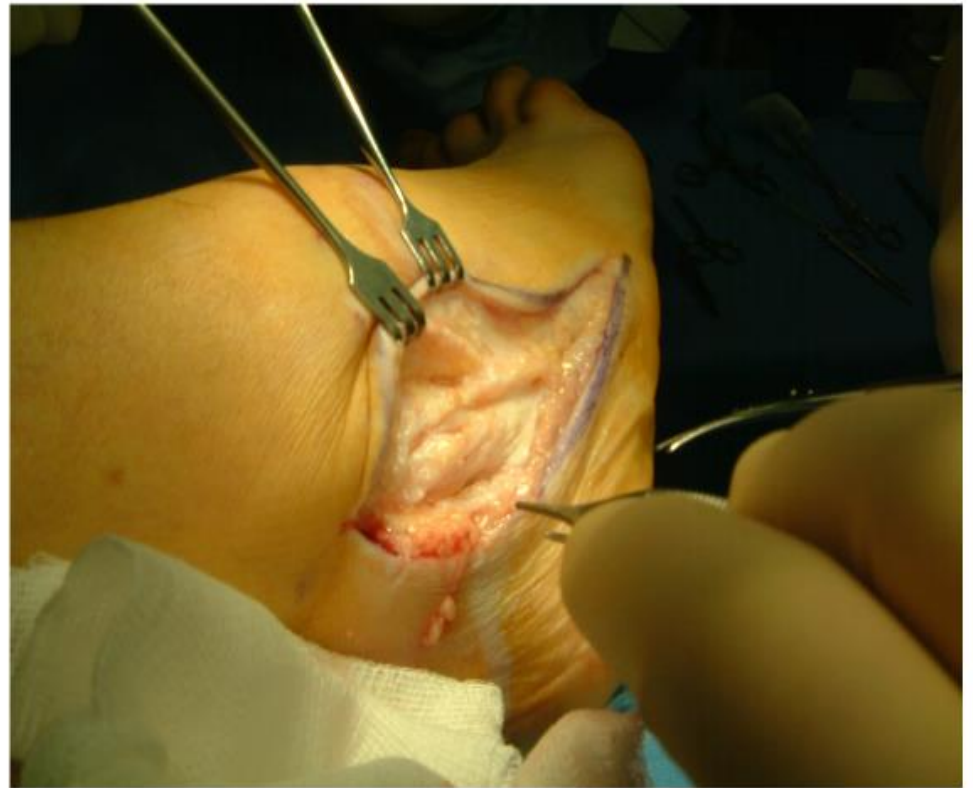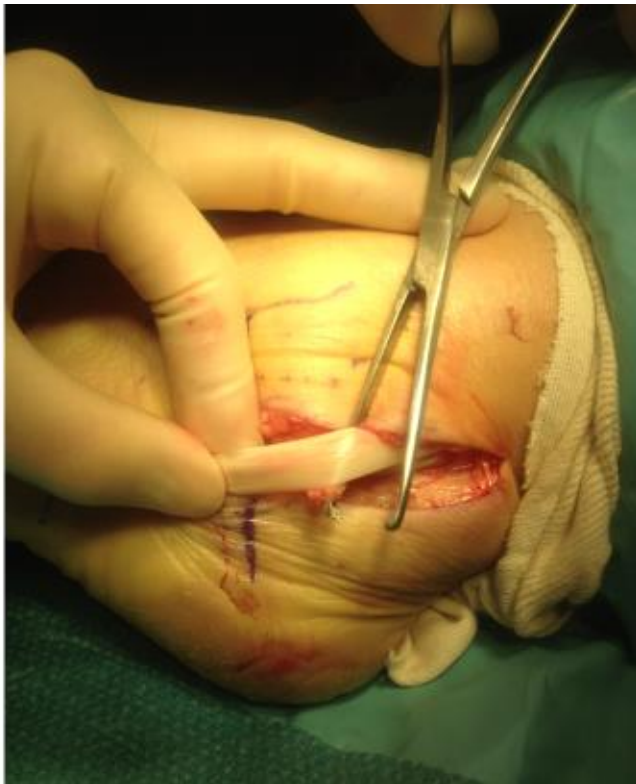Walking on Marbles



Joint Preservation

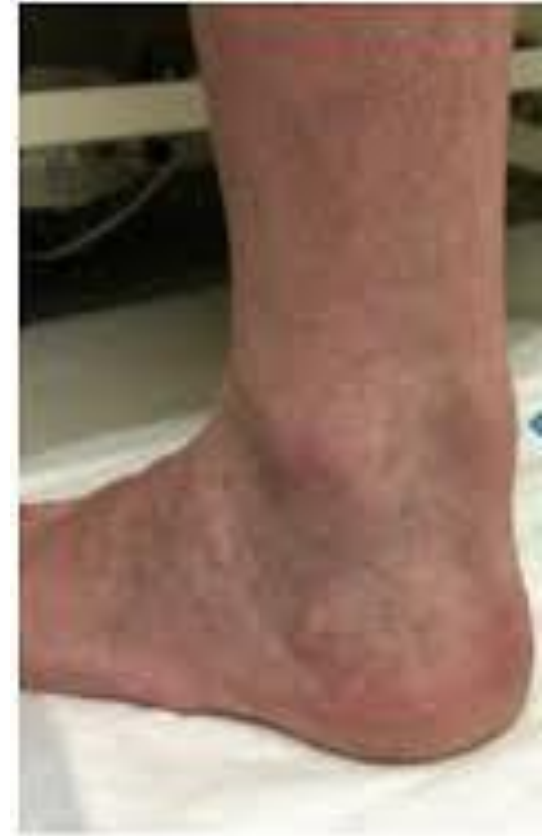

Haglund's/Tendon



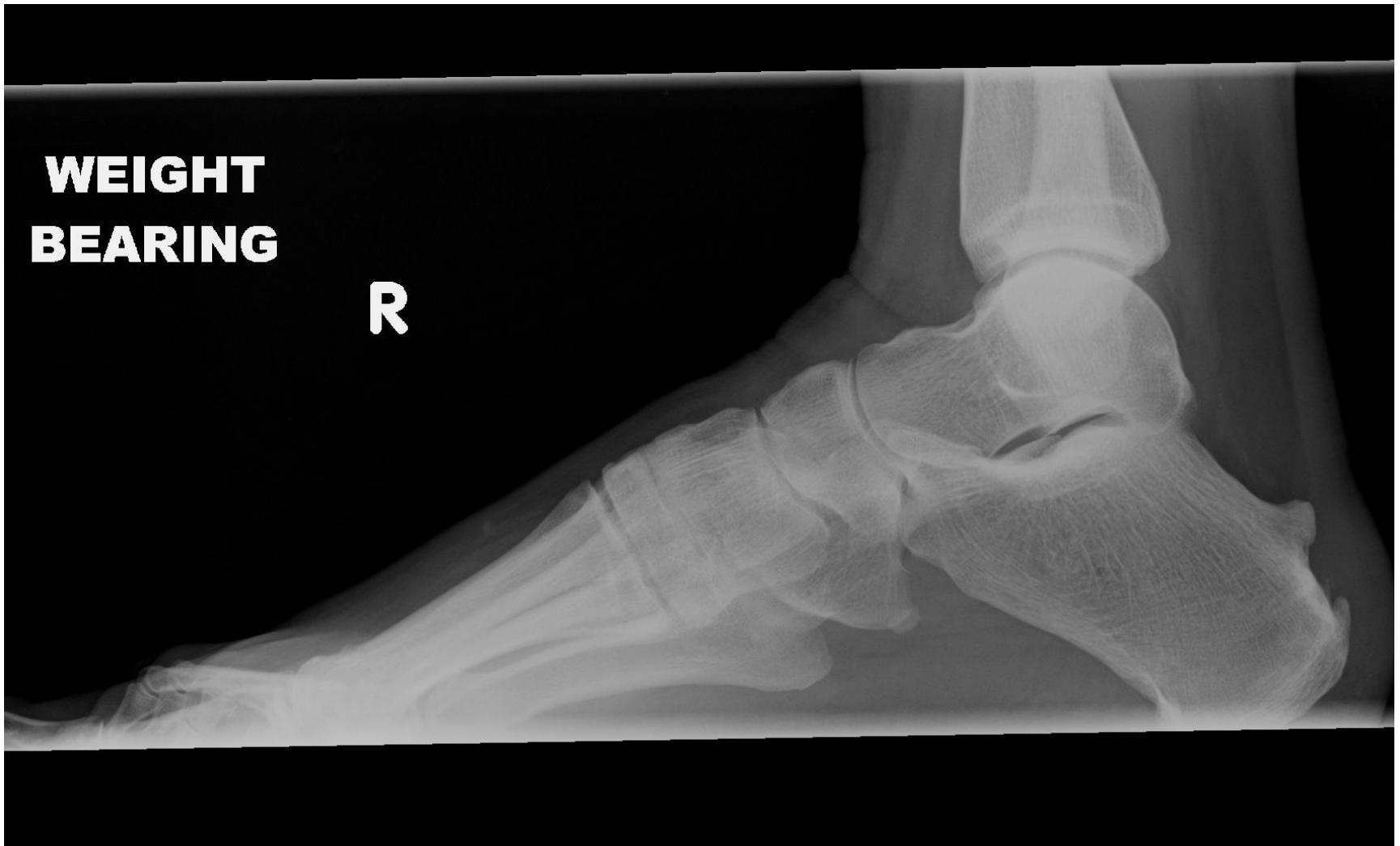Achilles Tendinopathy

- Address Pronation if present
- Stretches/Physio
- Scan
- Neo-Vascularisation?
- PRP
- ECSWT
- High Volume Injection

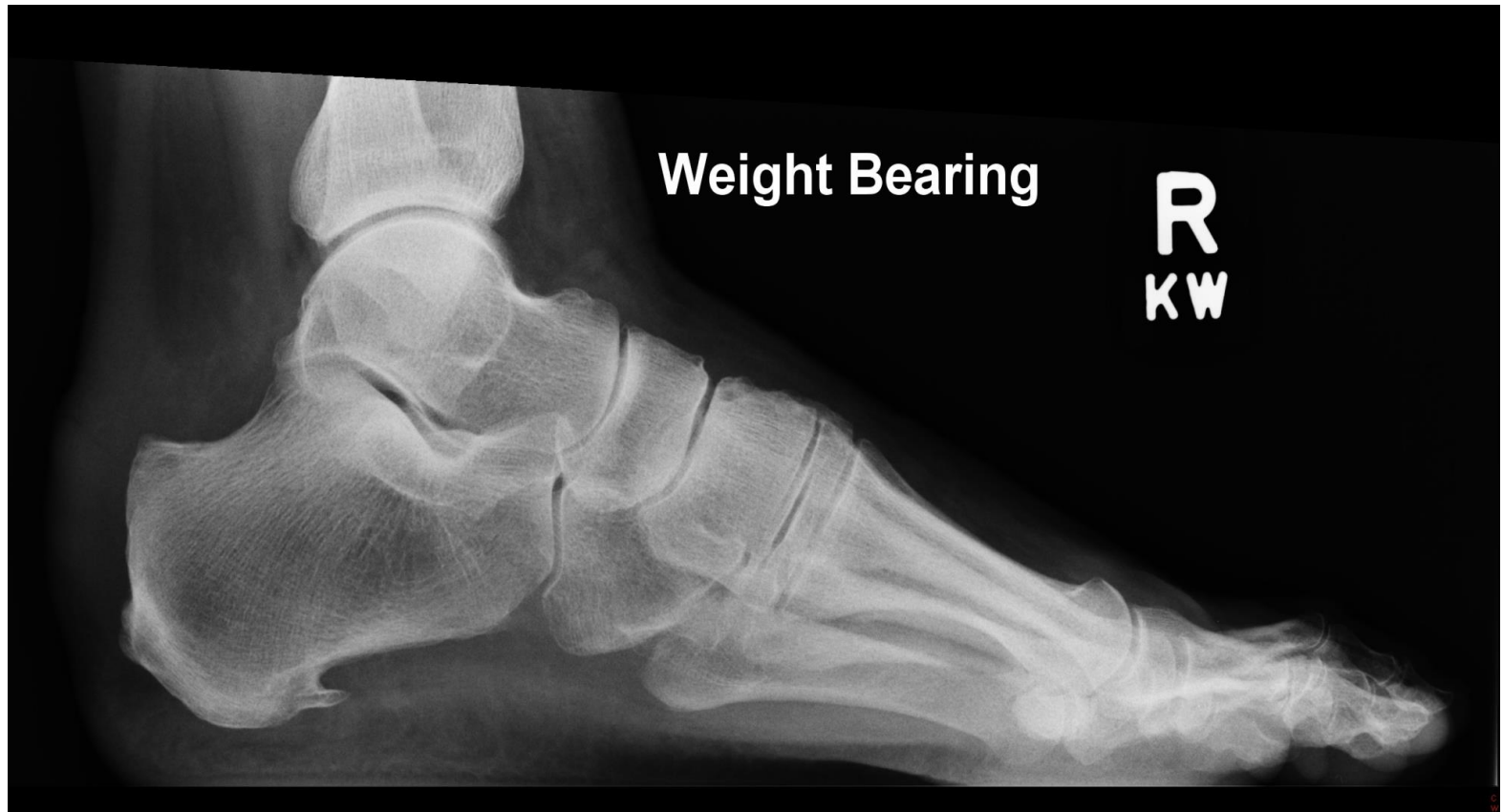

**WEIGHT
BEARING**

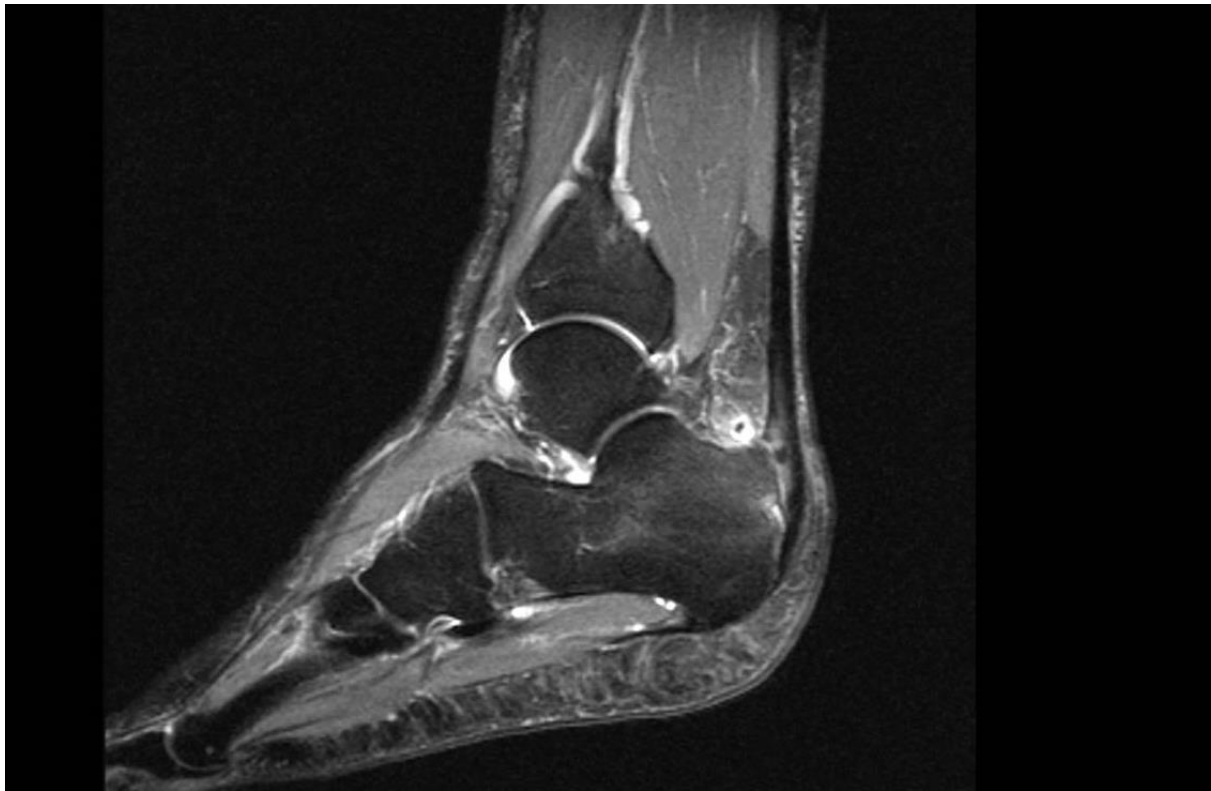
R



Achilles Tendinopathy/Haglund's

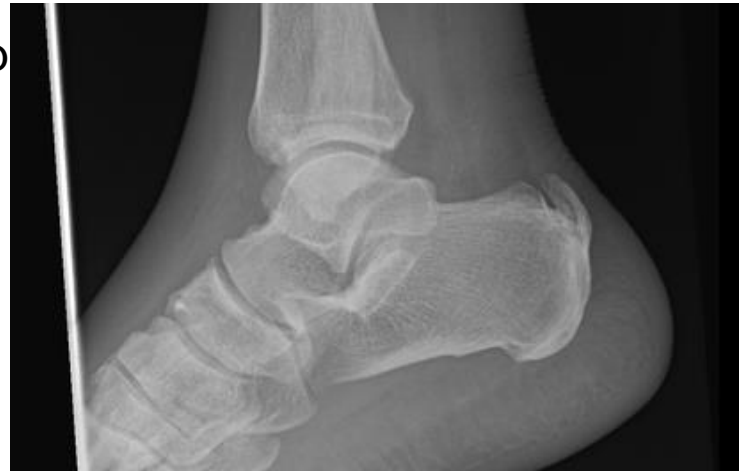

Haglund's Retro calcaneal Bursitis

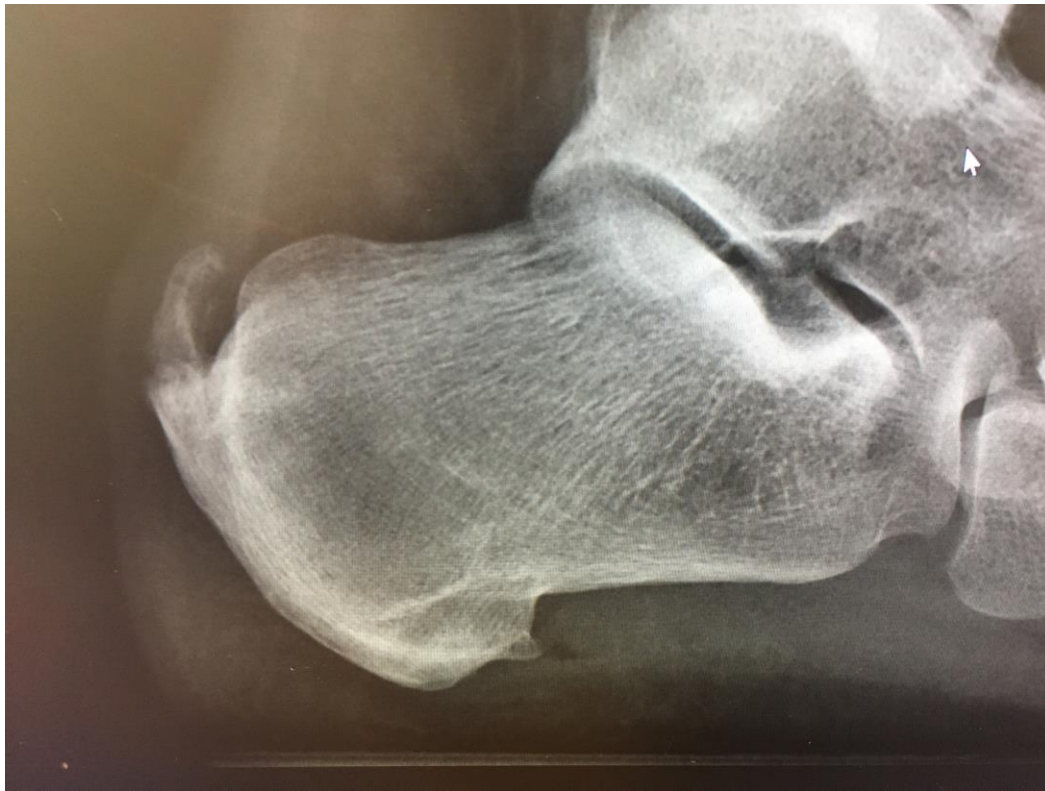

Enthesopathy and Psoriatic Arthropathy

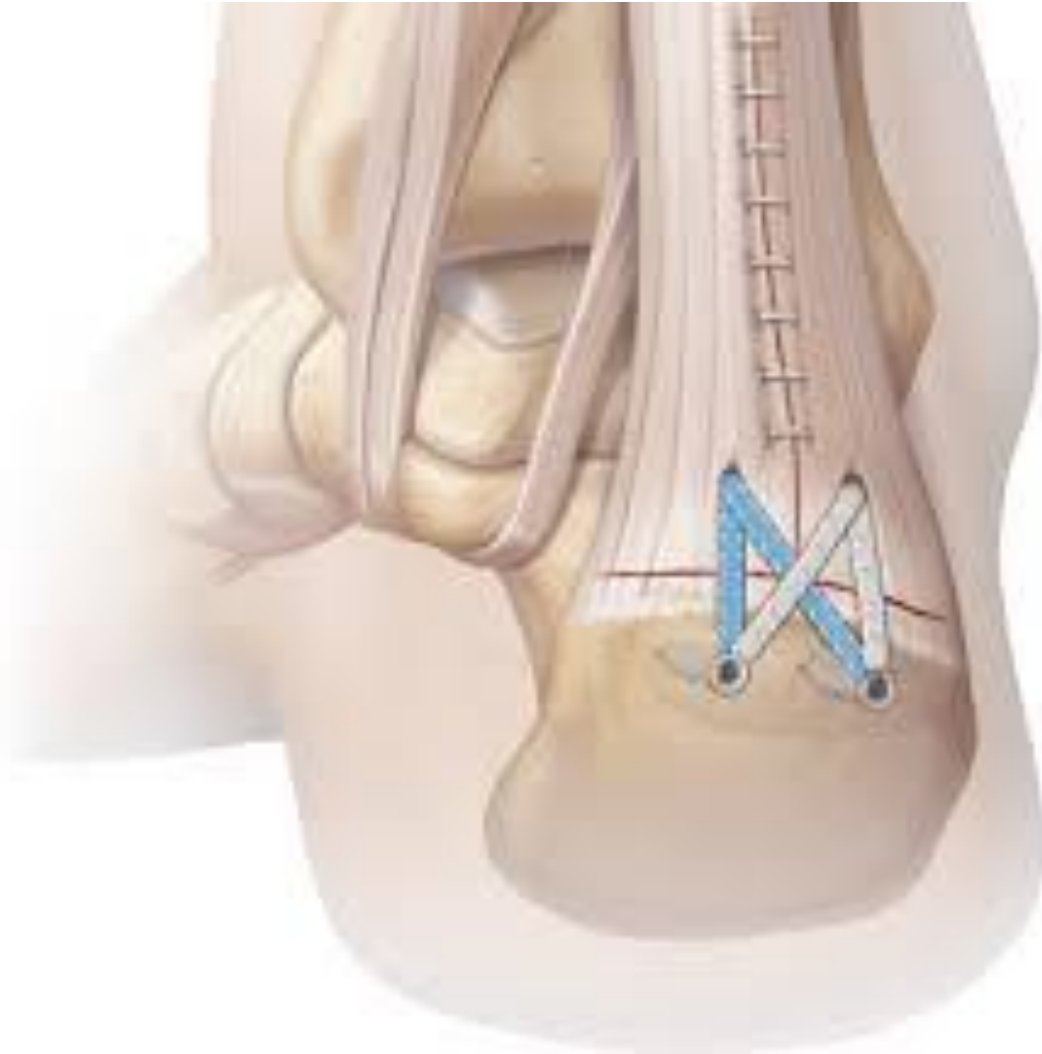
- Patience A, Steultjens MP, Hendry GJ.
- **Ultrasound features of Achilles enthesitis in psoriatic arthritis: a systematic review.**
- Rheumatol Adv Pract. 2021 Nov 5;5(Suppl 1):10.1093/rap/rkab056. PMID: 347
- Changes noted include
 - Hypoechogenicity [mean 5.9% (s.d. 0.9)],
 - Increased thickness [mean 22.1% (s.d. 12.2)],
 - Erosions [mean 3.3% (s.d. 2.5)],
 - Calcifications [mean 42.6% (s.d. 15.6)],
 - Enthesophytes [mean 41.3% (s.d. 15.6)] and
 - Doppler signal [mean 11.8% (s.d. 10.1)].

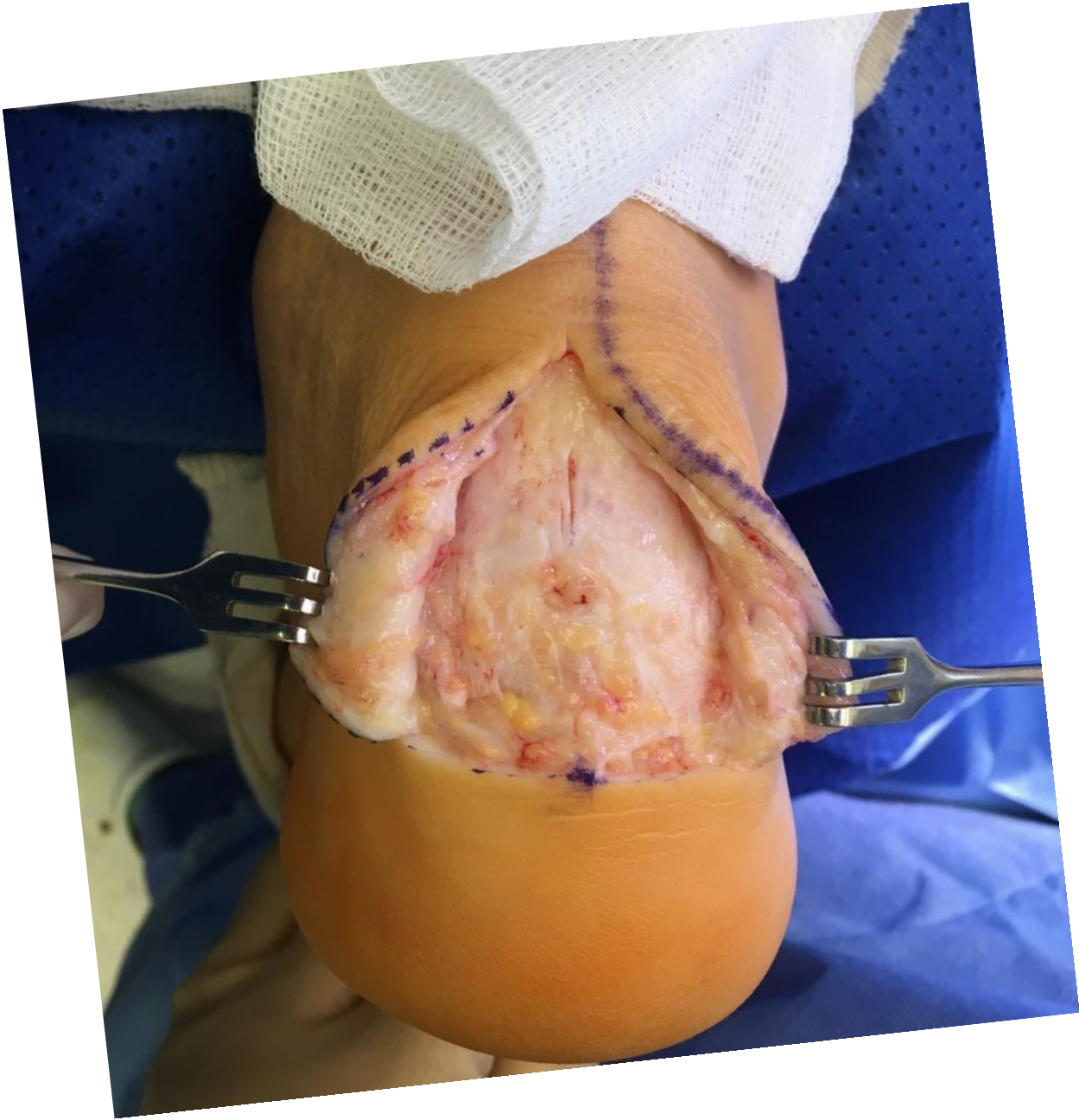

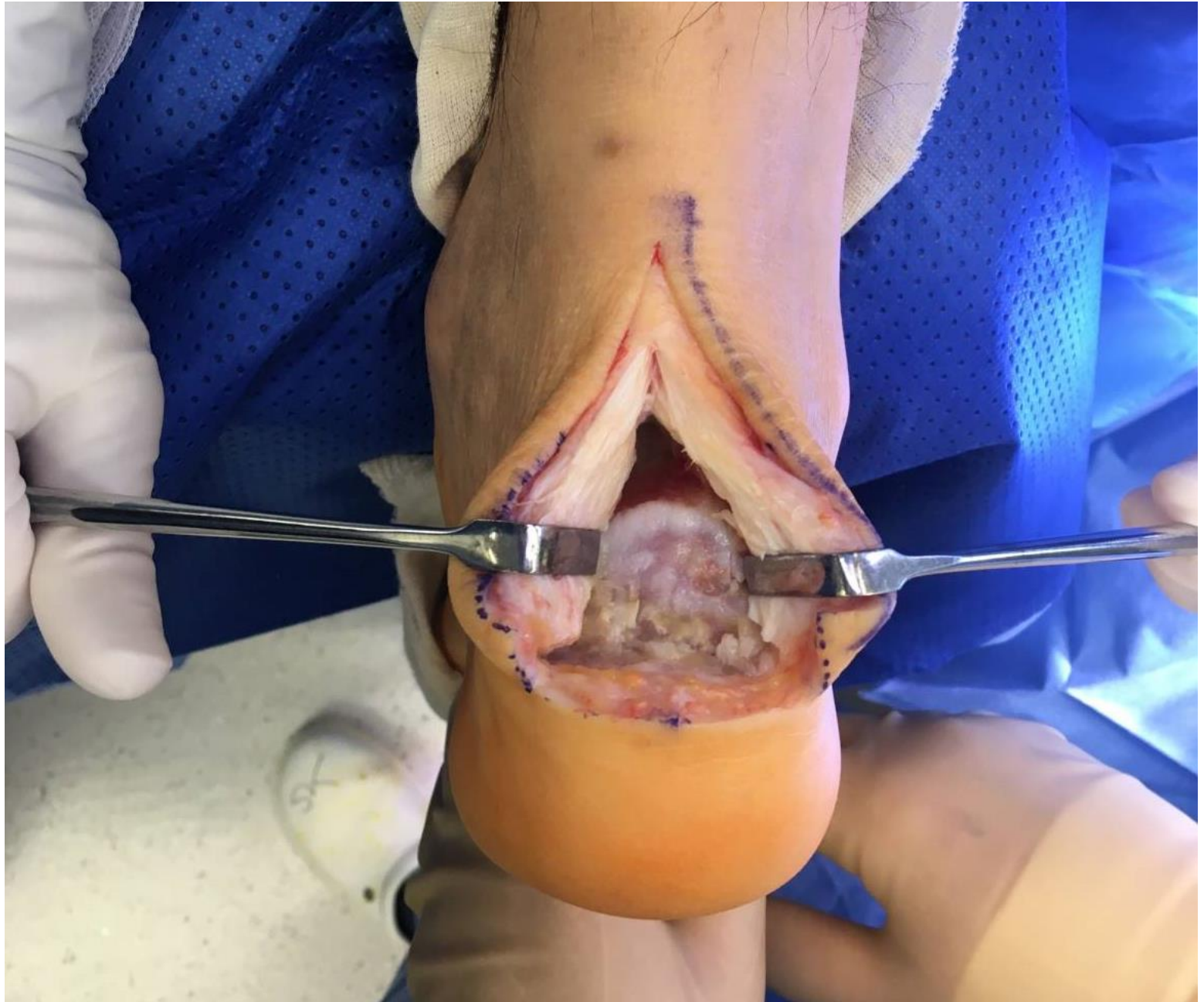
Bone Proliferation

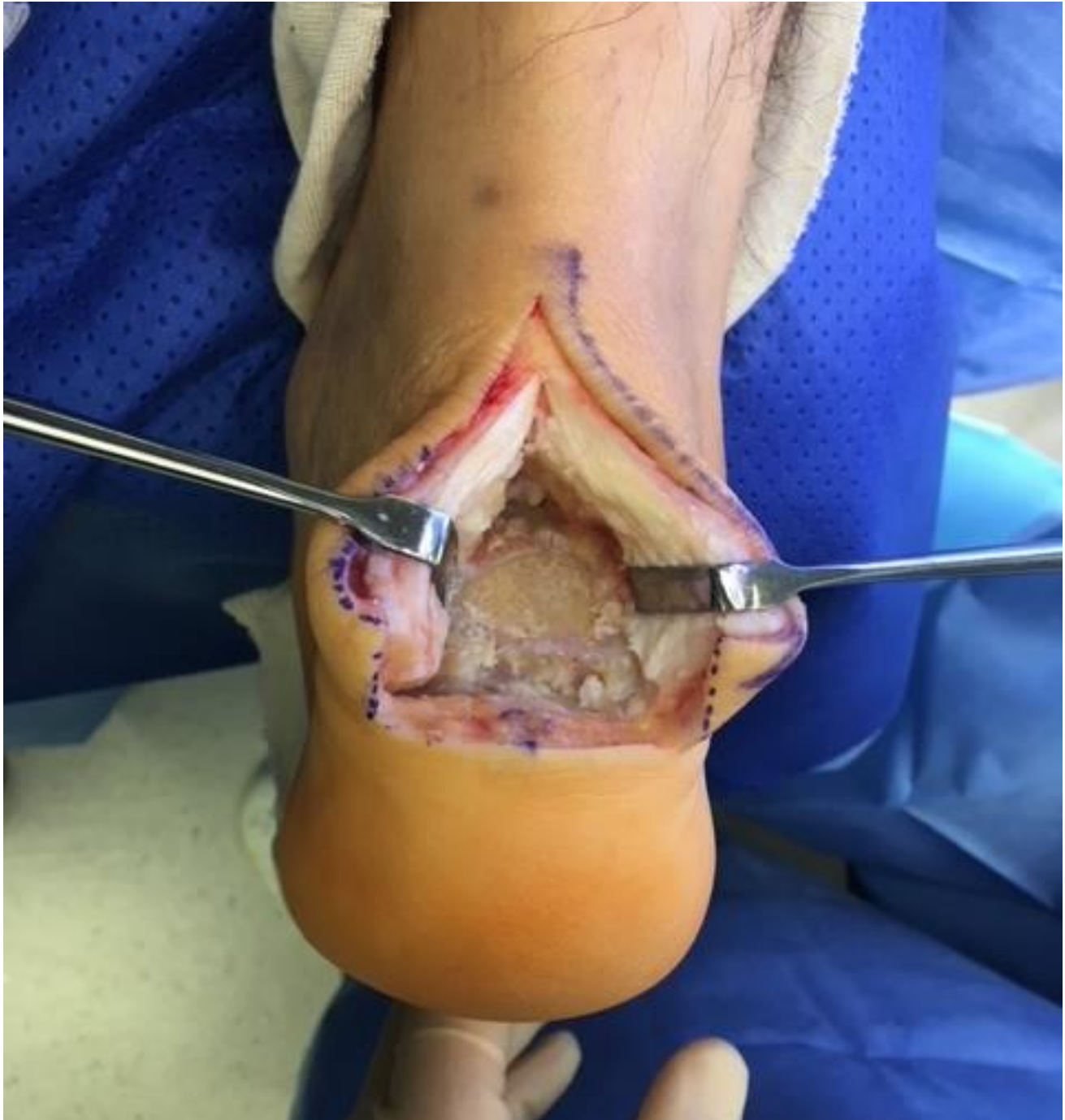

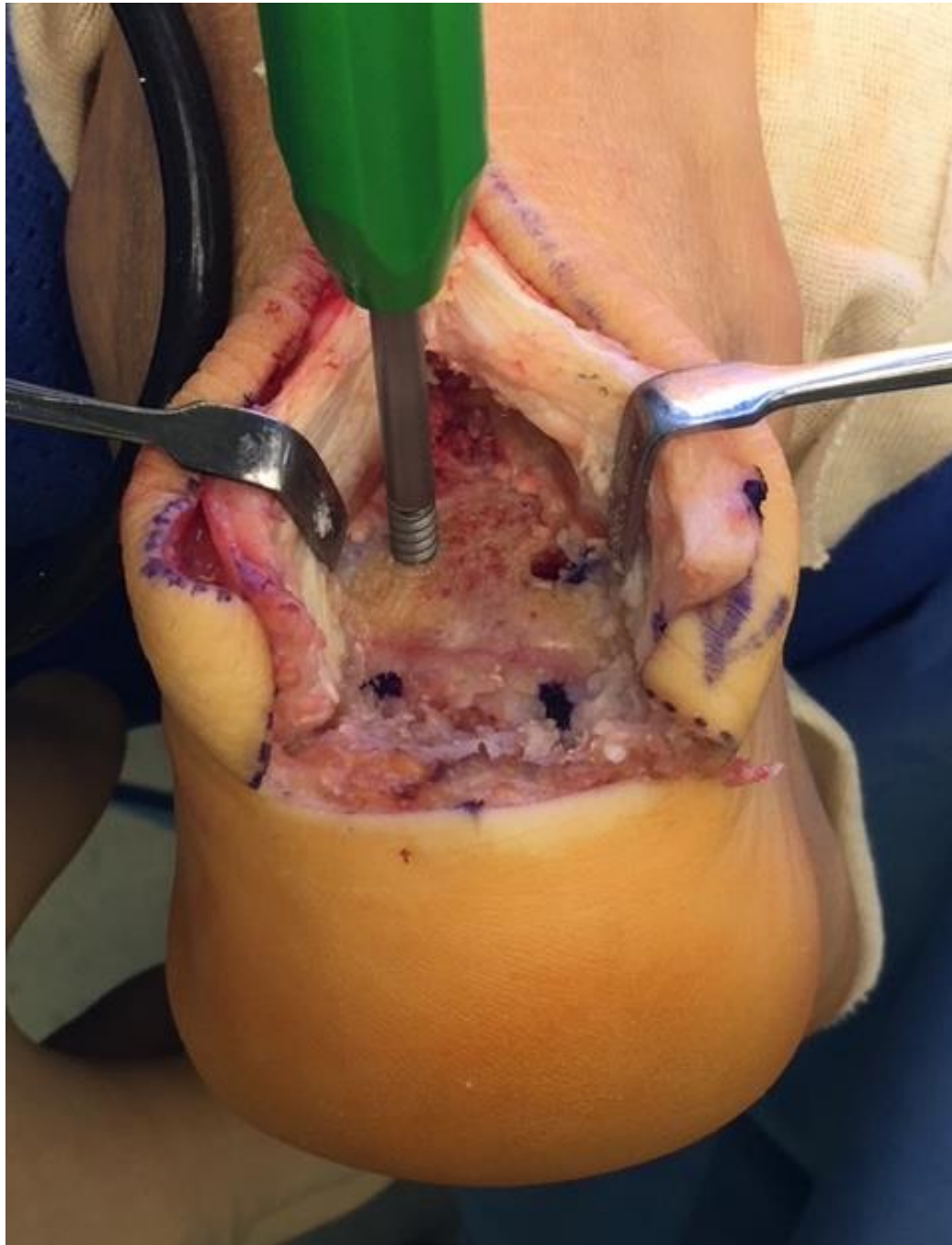
Speedbridge

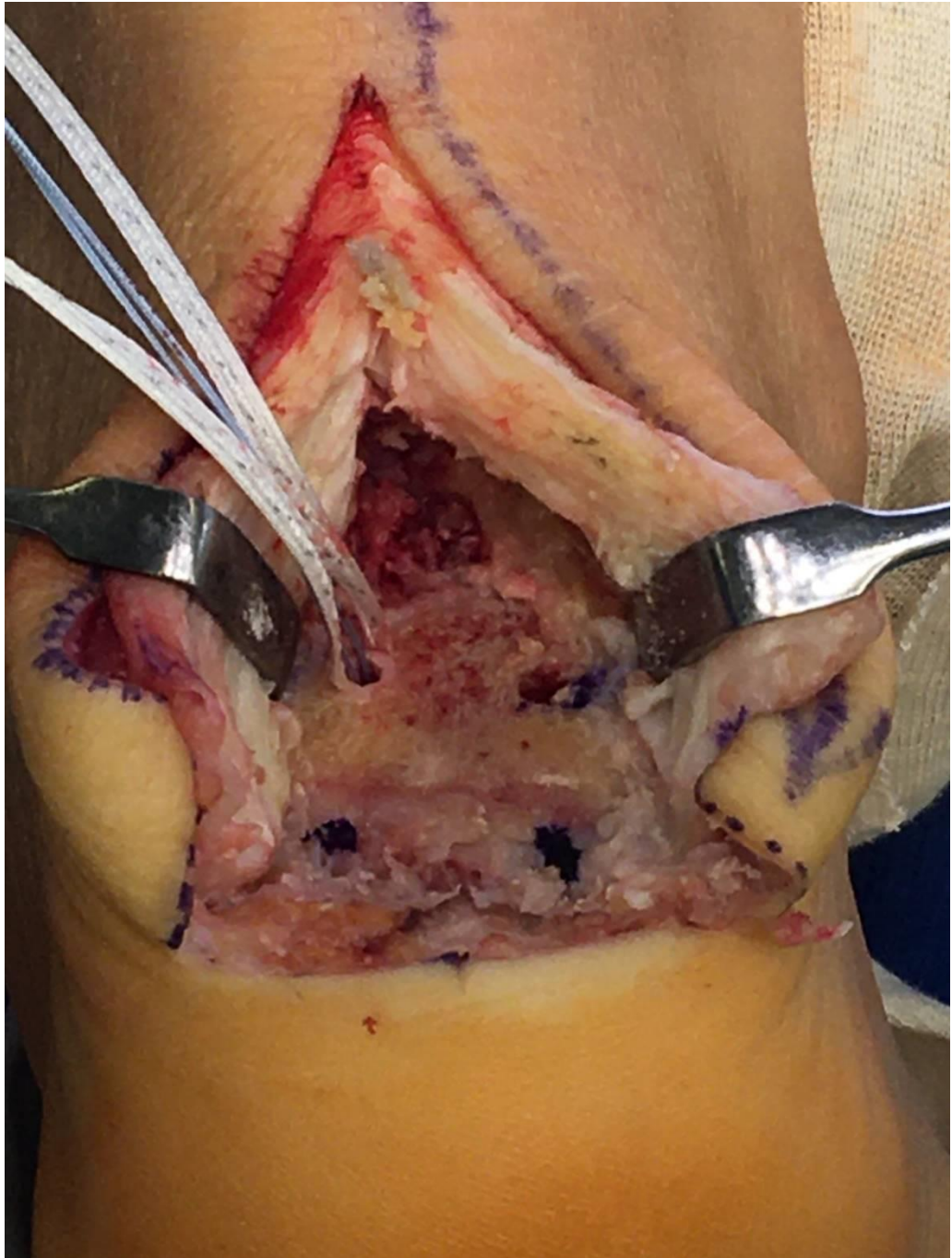


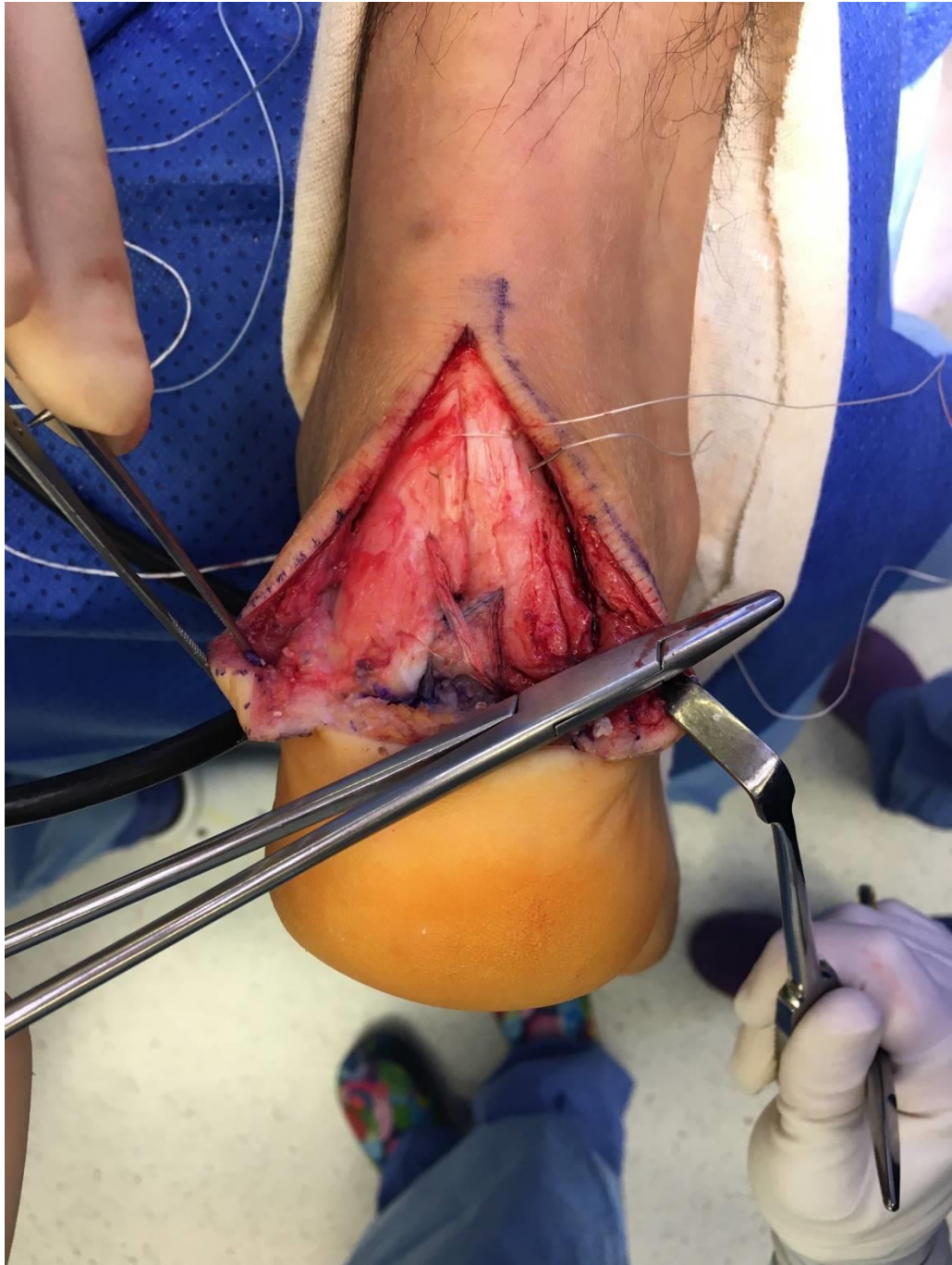




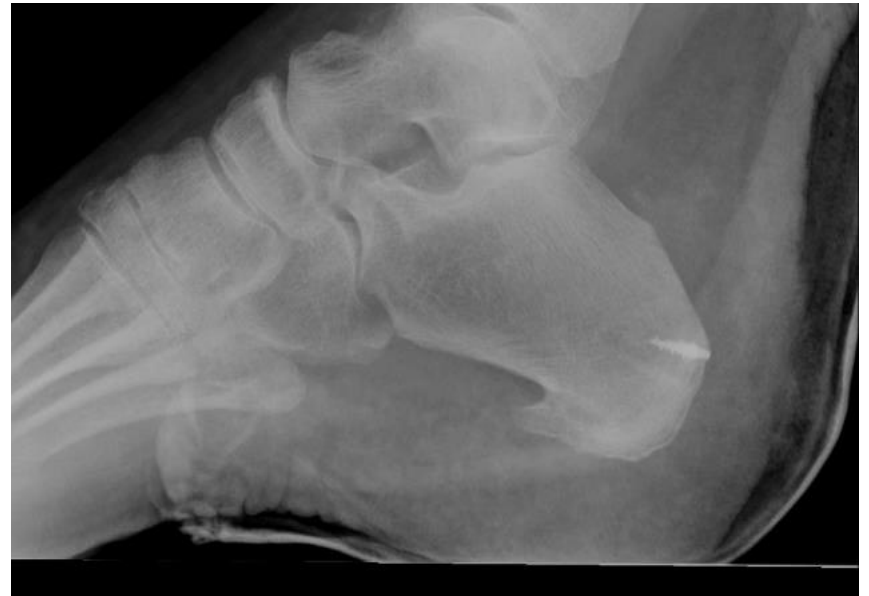
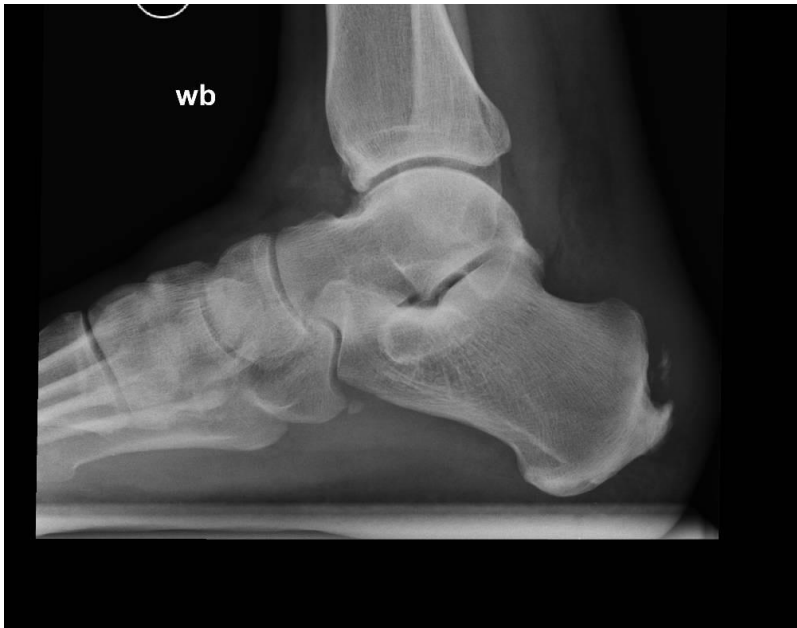


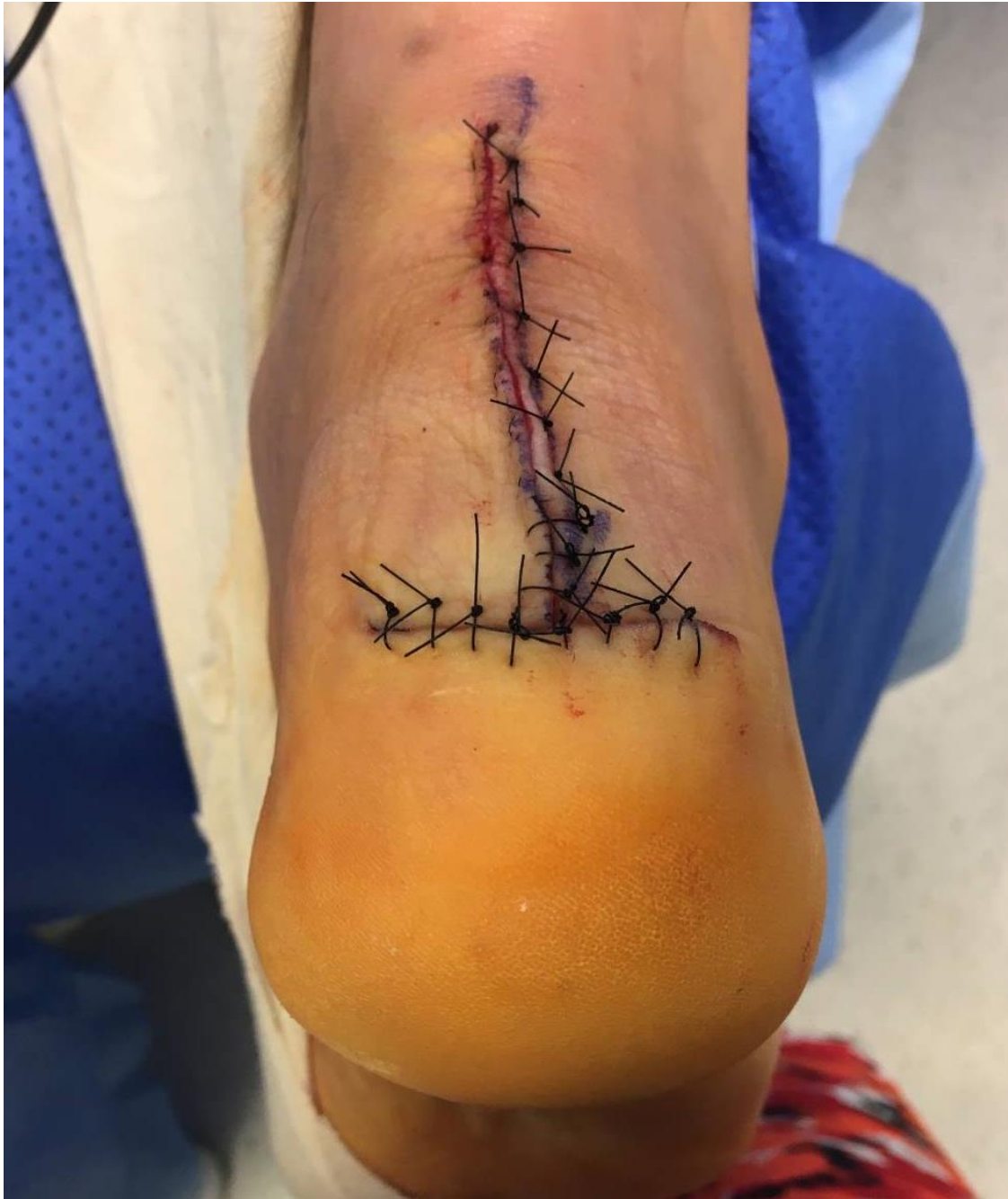


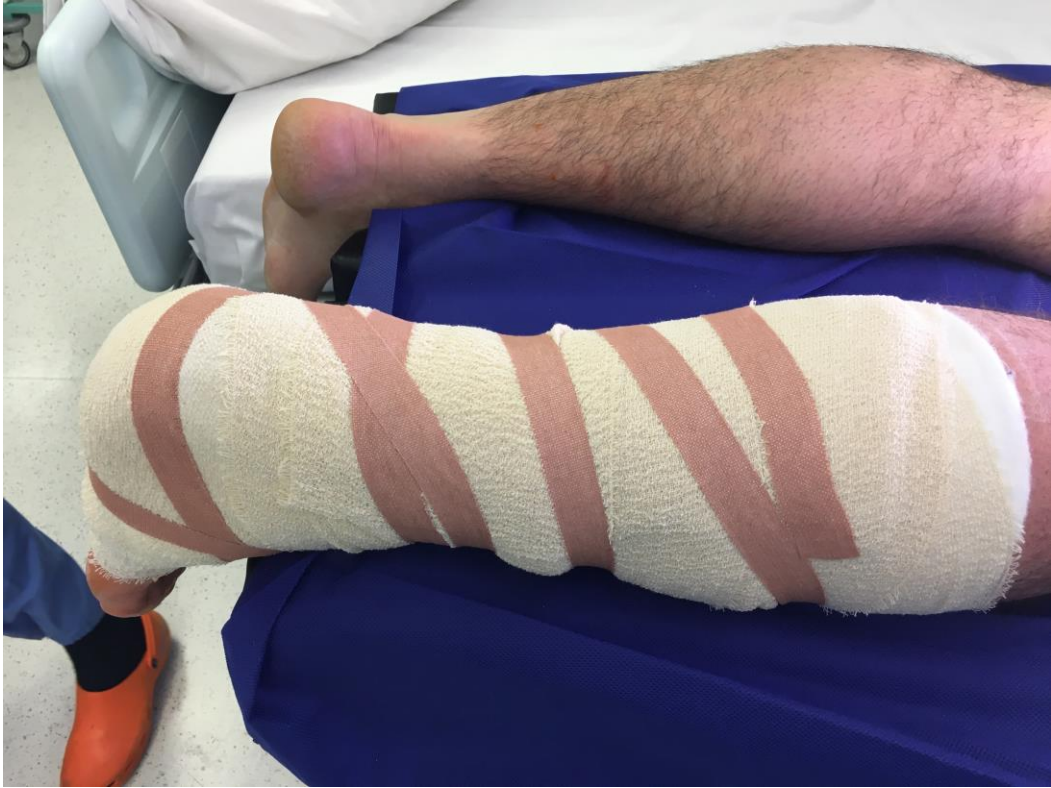
Before and After







- Thanks for Listening
- Steve Kriss
- footsurgery.uk.com

